Dermatopathology Slide Review Part 41

Paul K. Shitabata, M.D.
Dermatopathology Institute

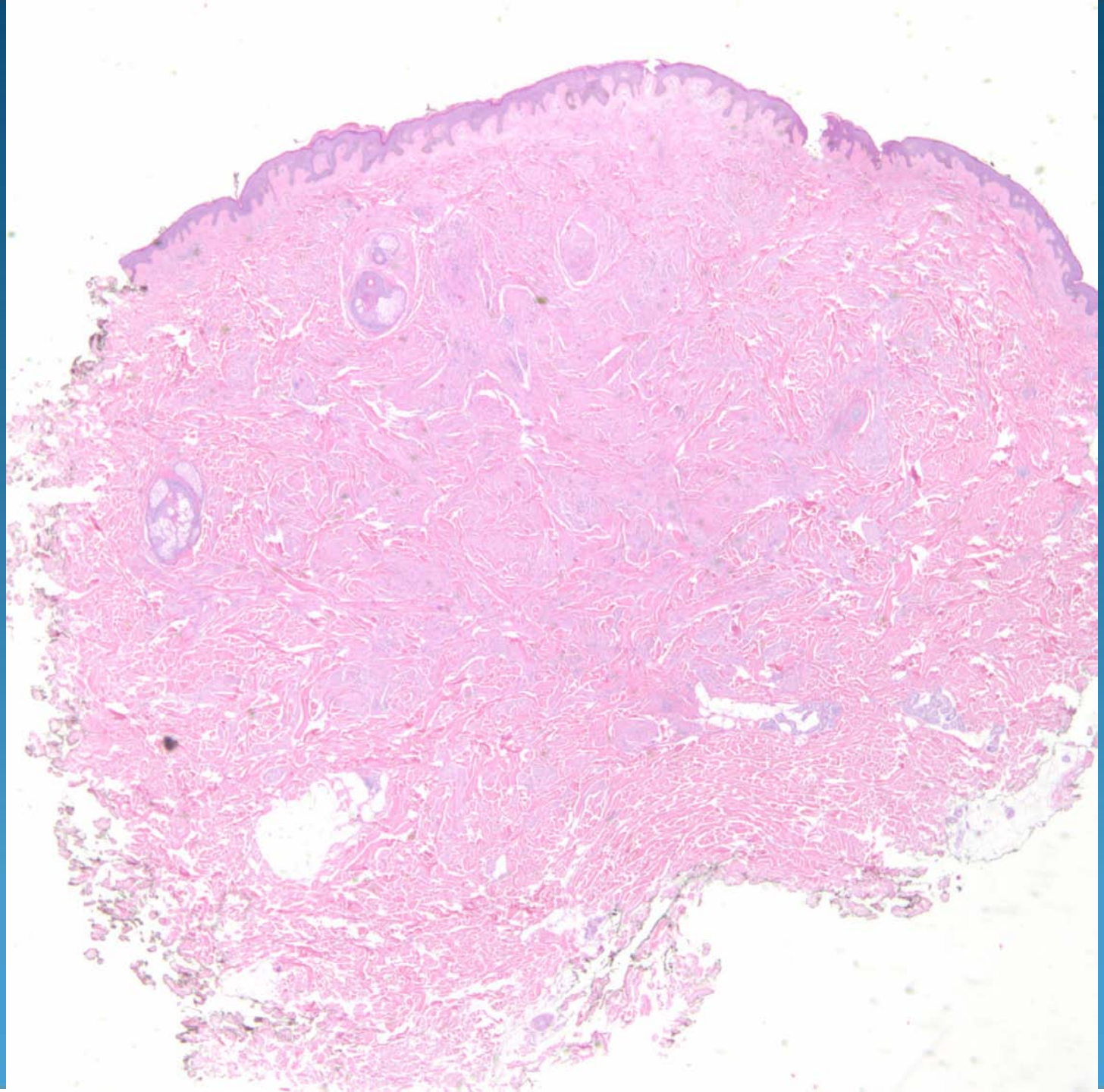

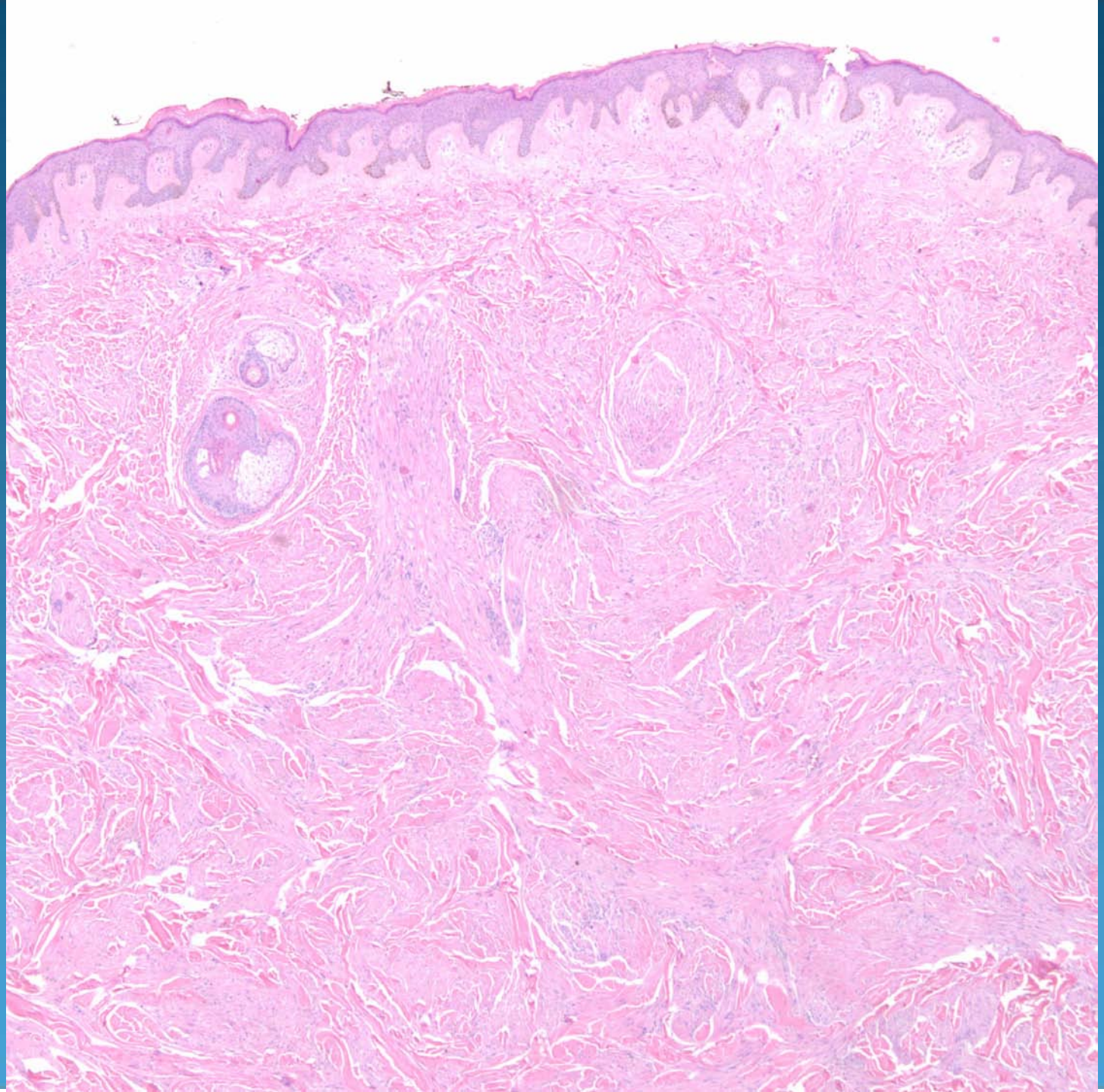

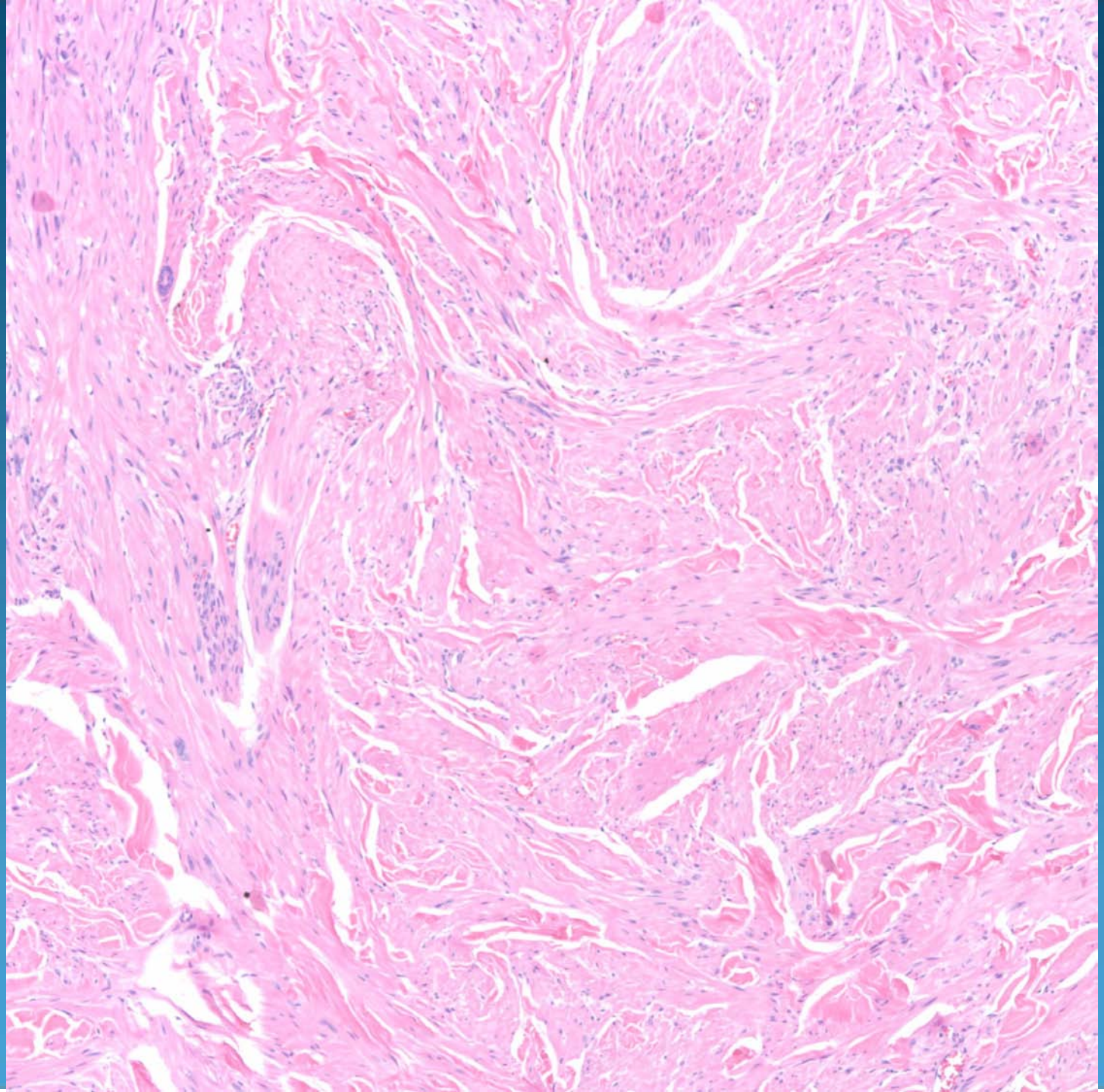

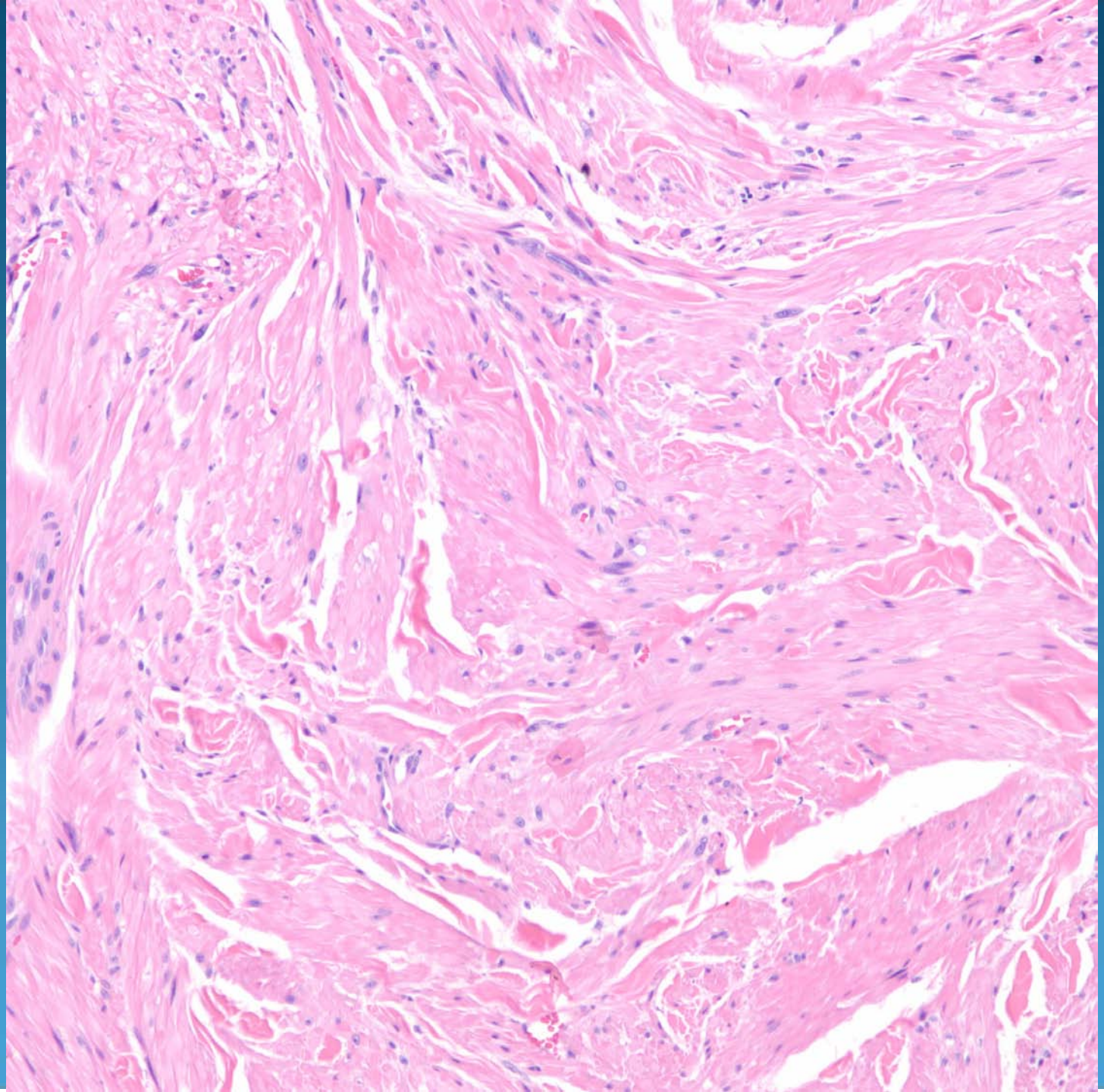

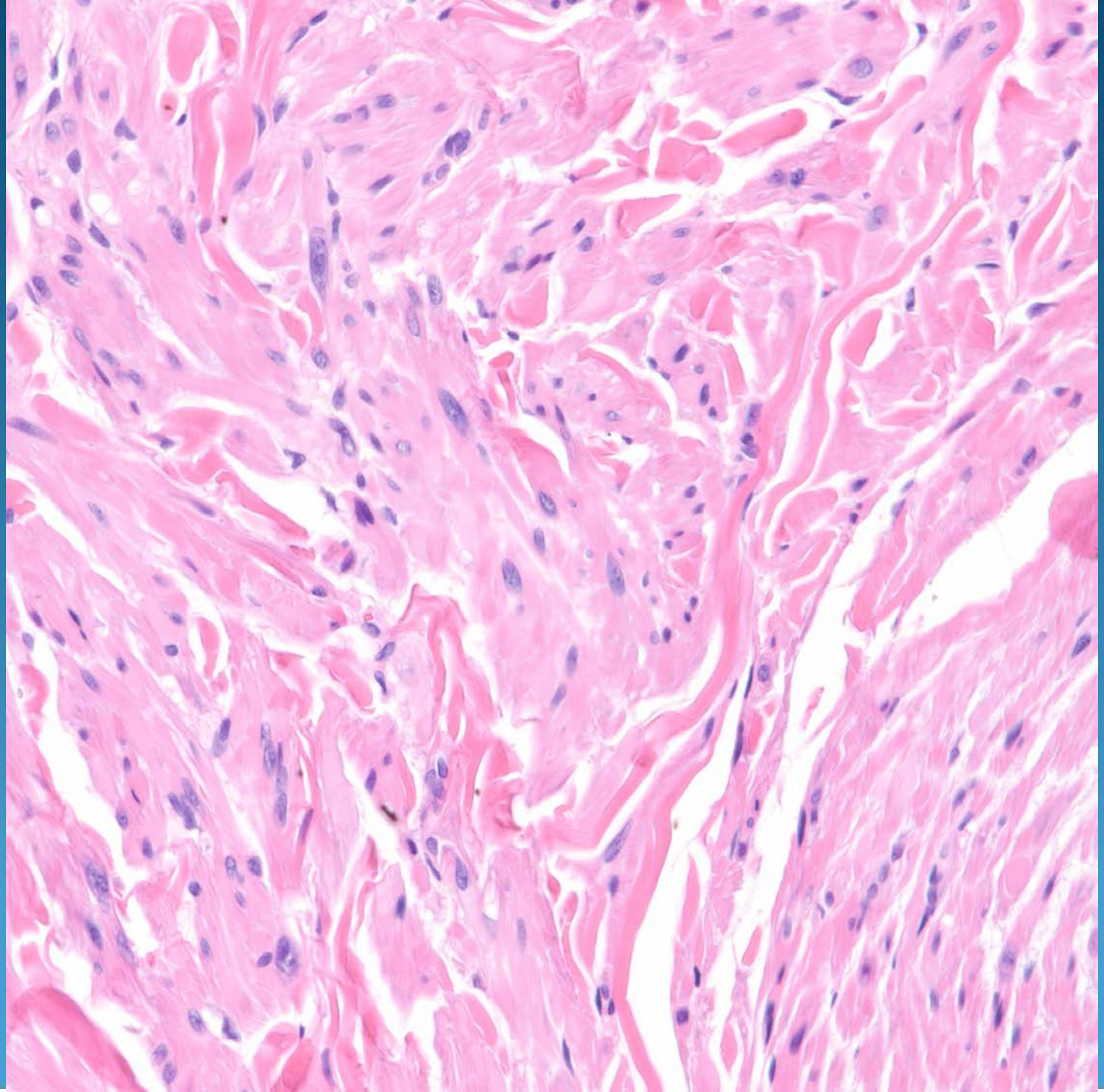

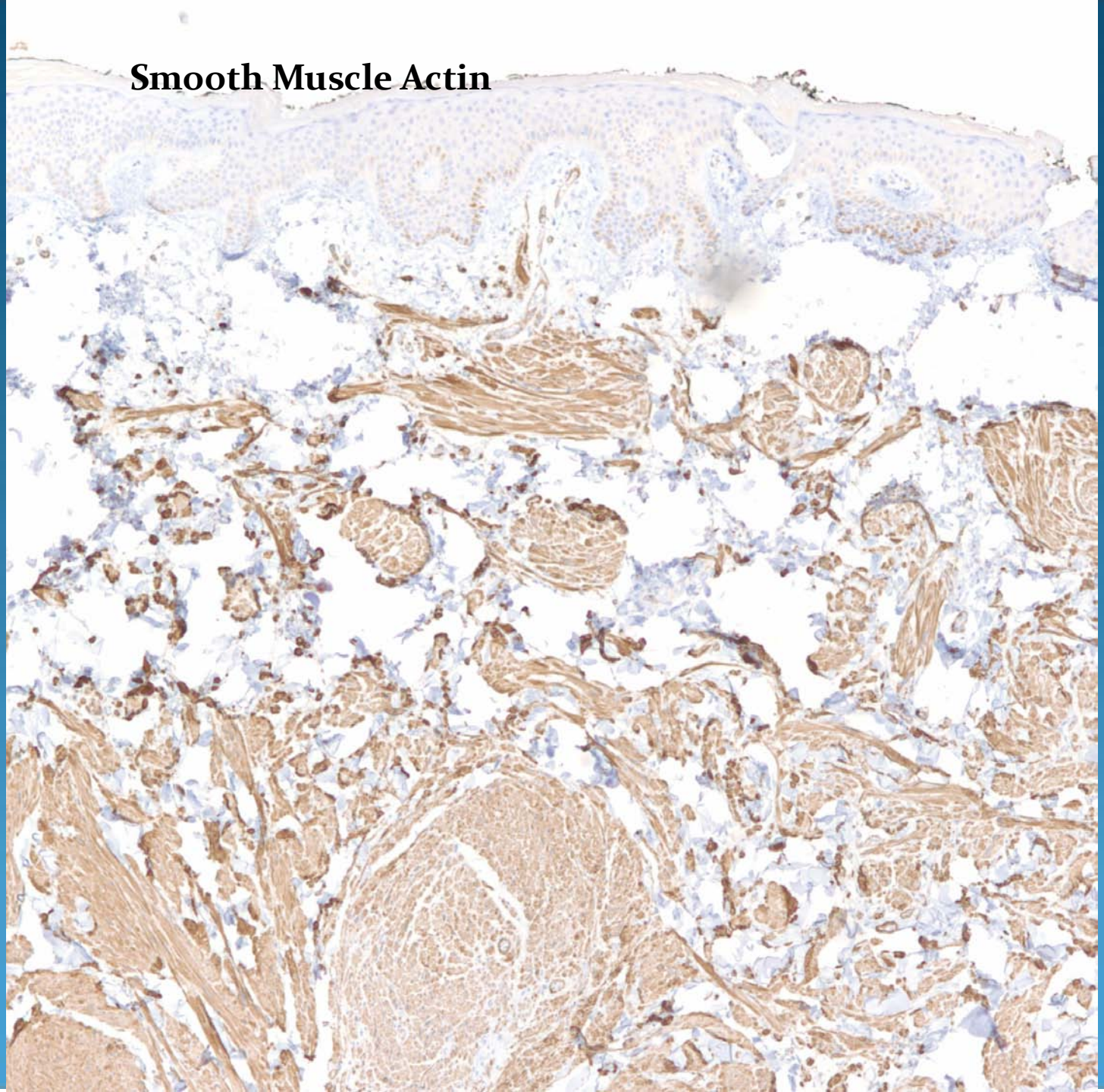
Smooth Muscle Actin

Cutaneous Leiomyoma

Pearls

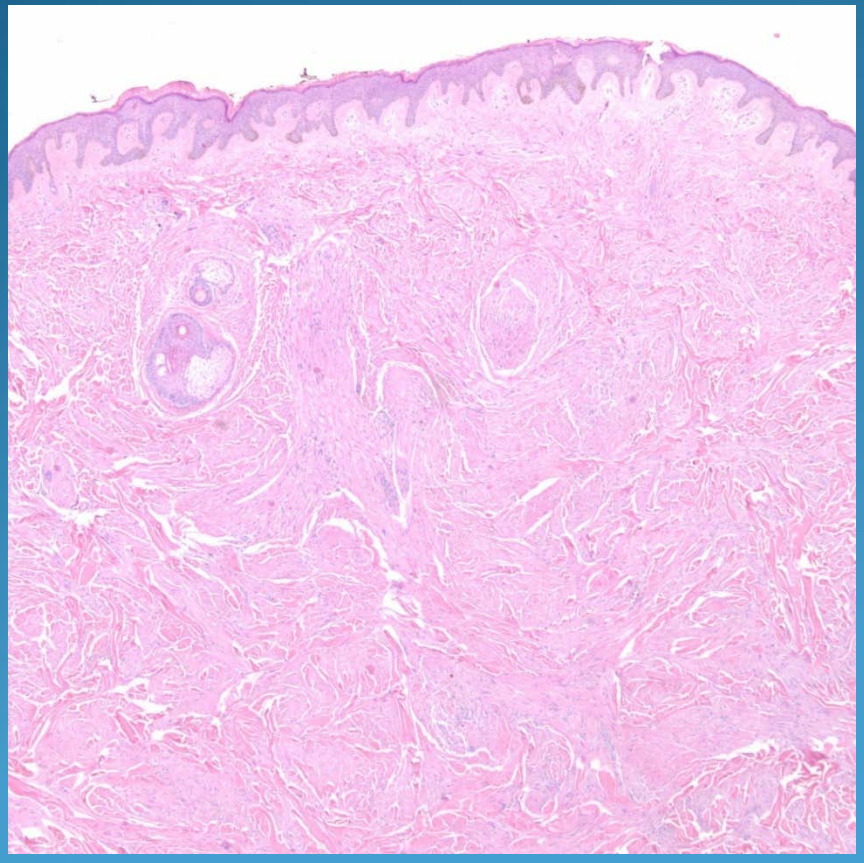

- Partly circumscribed collection of bland spindle cells, arranged in intersecting fascicles
- May show perinuclear halos
- Minimal atypia or mitotic figures
- Superficial tumors usually arising from pilar arrector muscle
- May need IHC to confirm

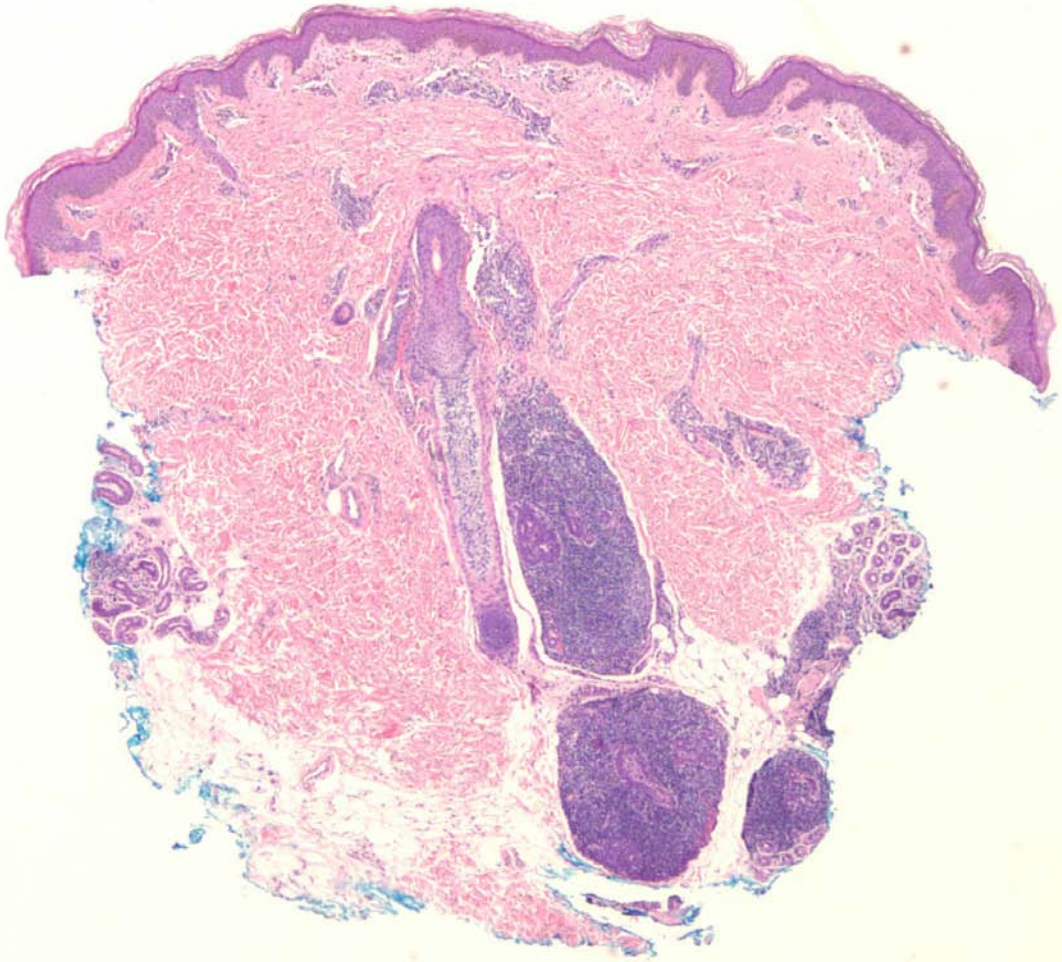

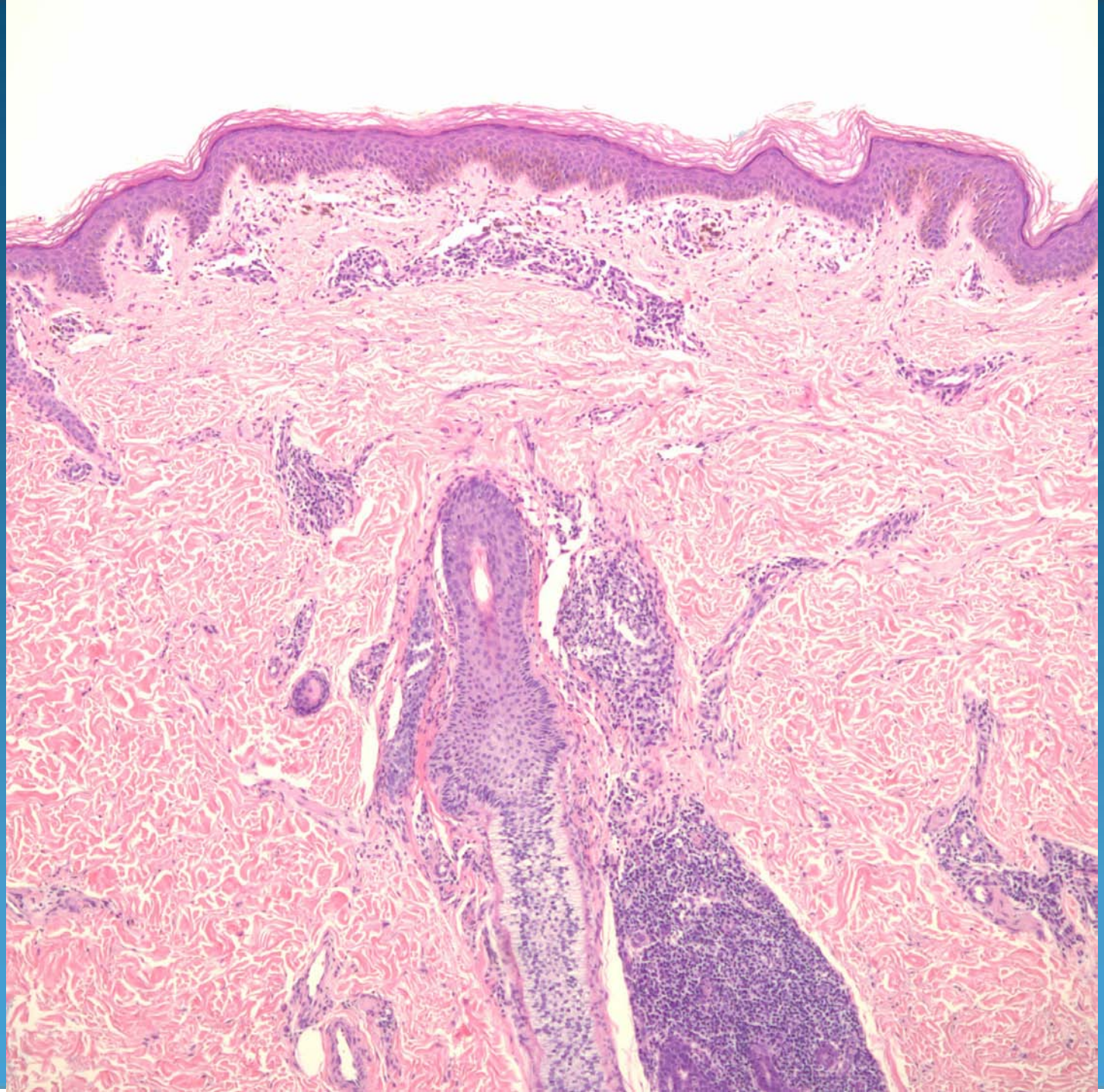

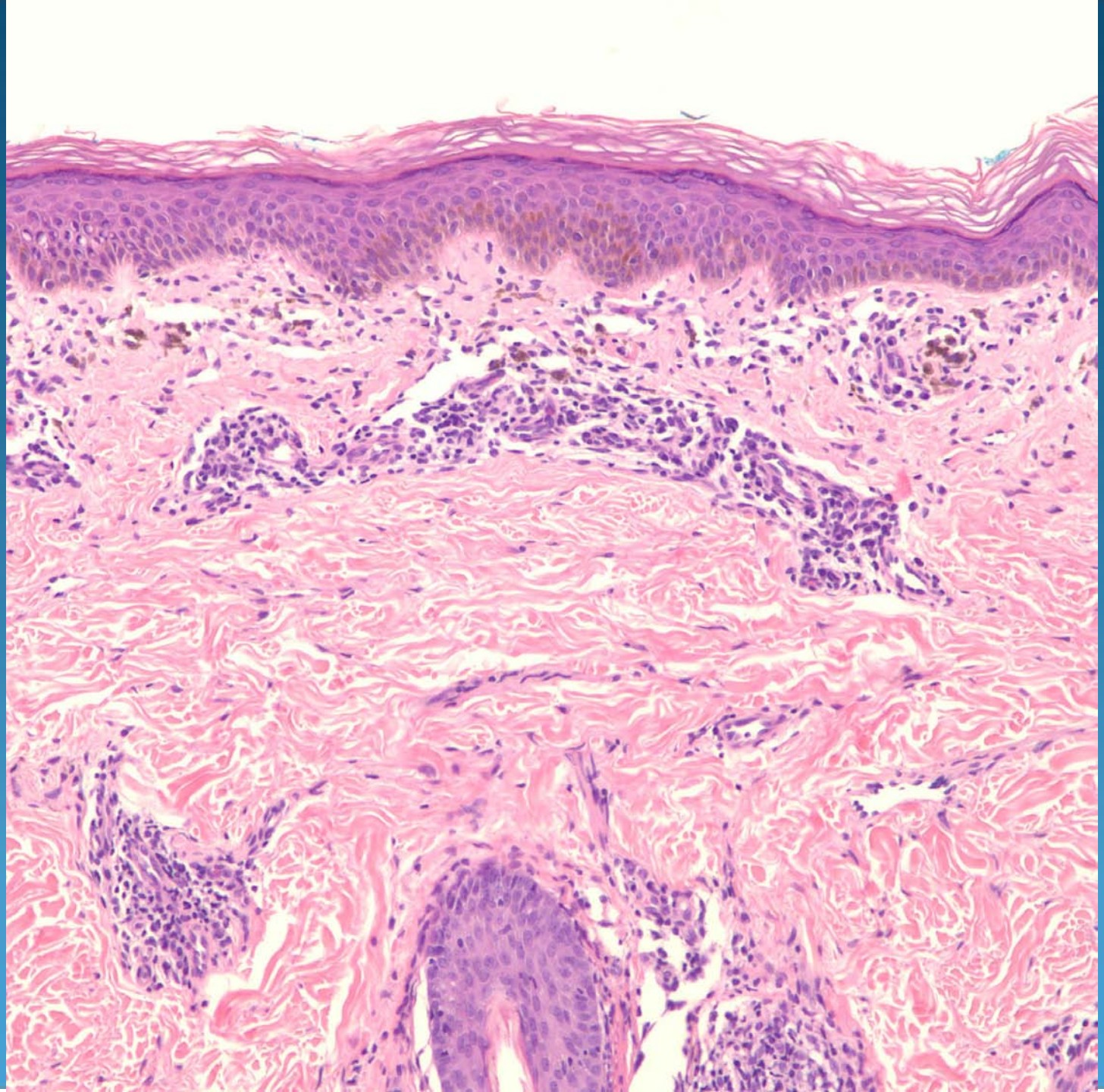

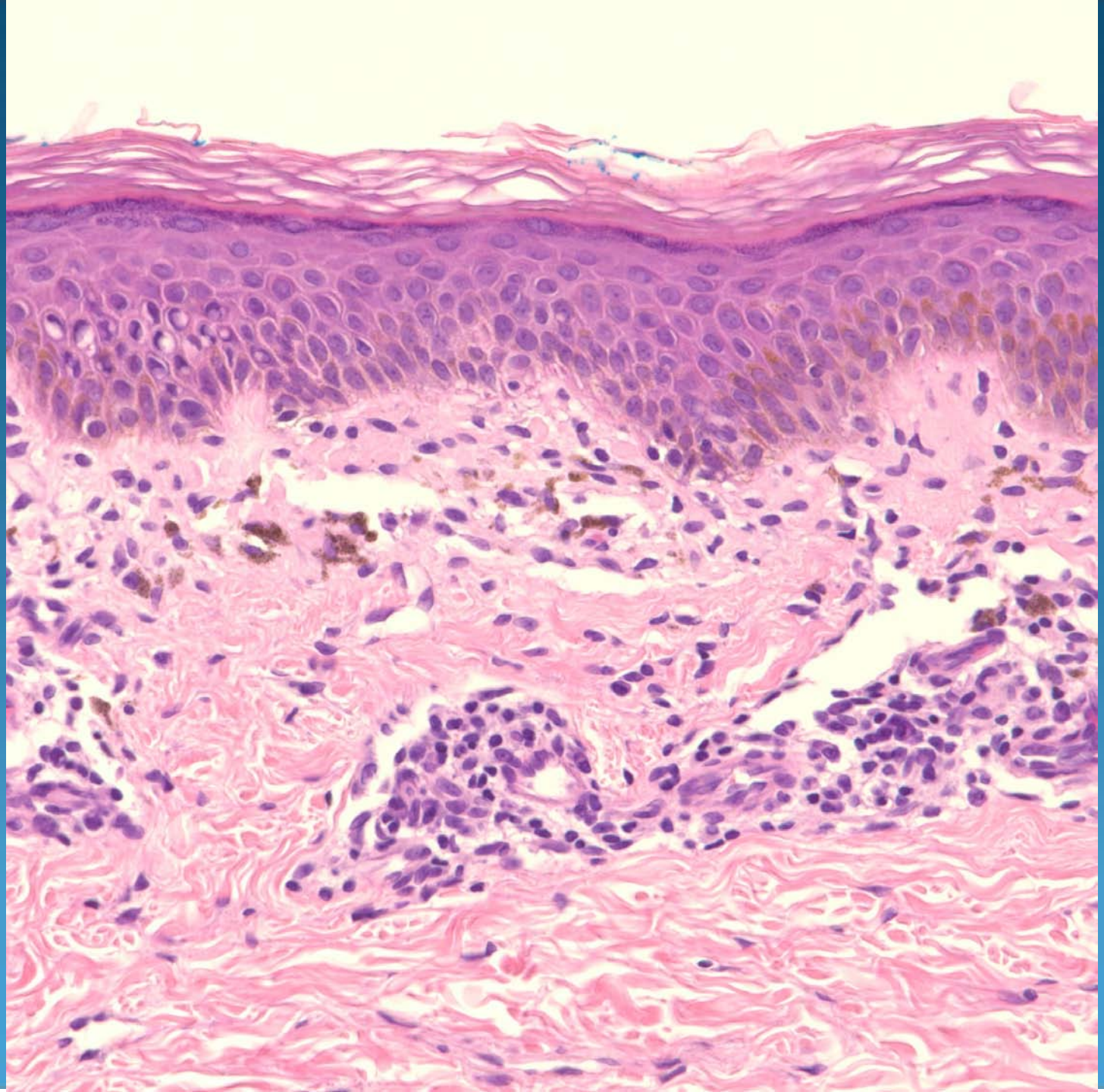

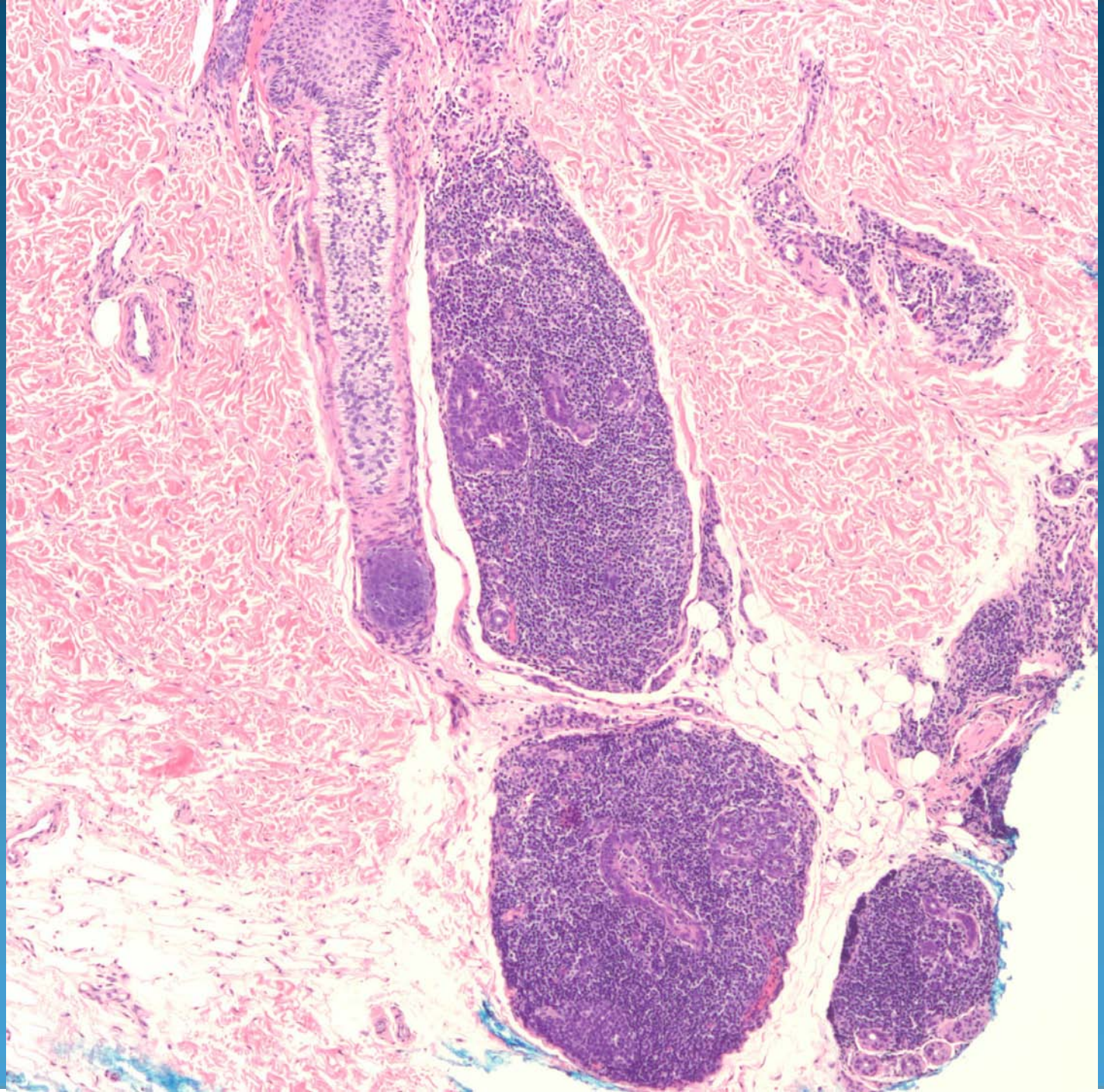

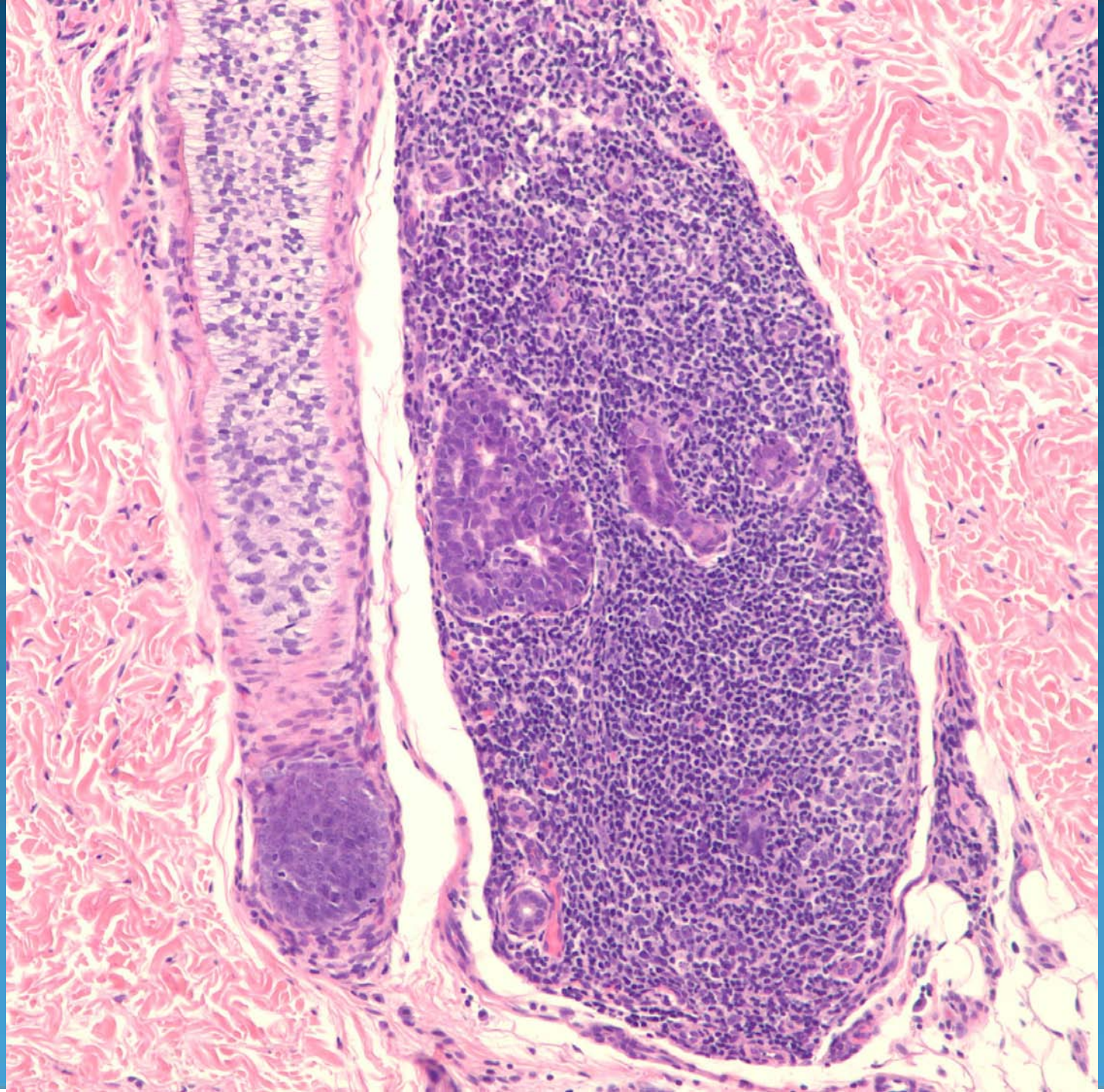

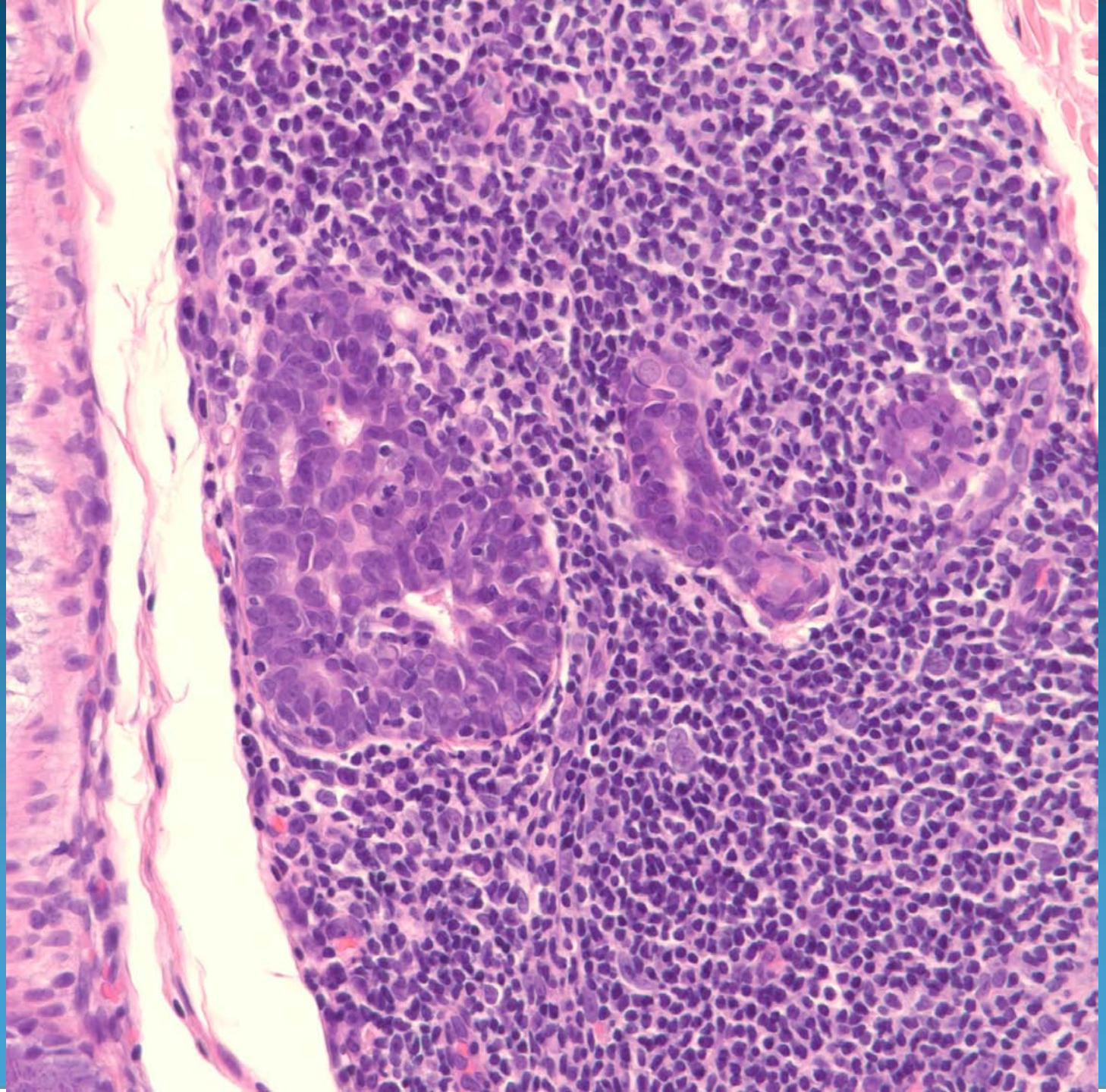

Lichen Striatus

Pearls

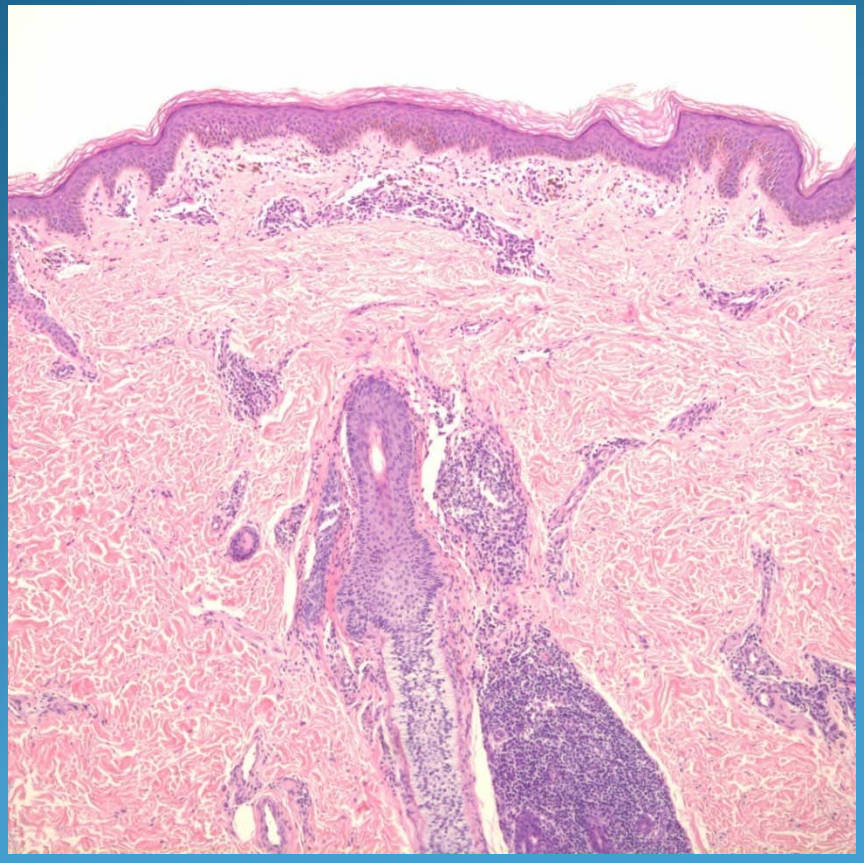

- Lichenoid interface dermatitis with superficial and deep perivascular and periadnexal lymphocytic infiltrate
- Clinical-pathologic correlation

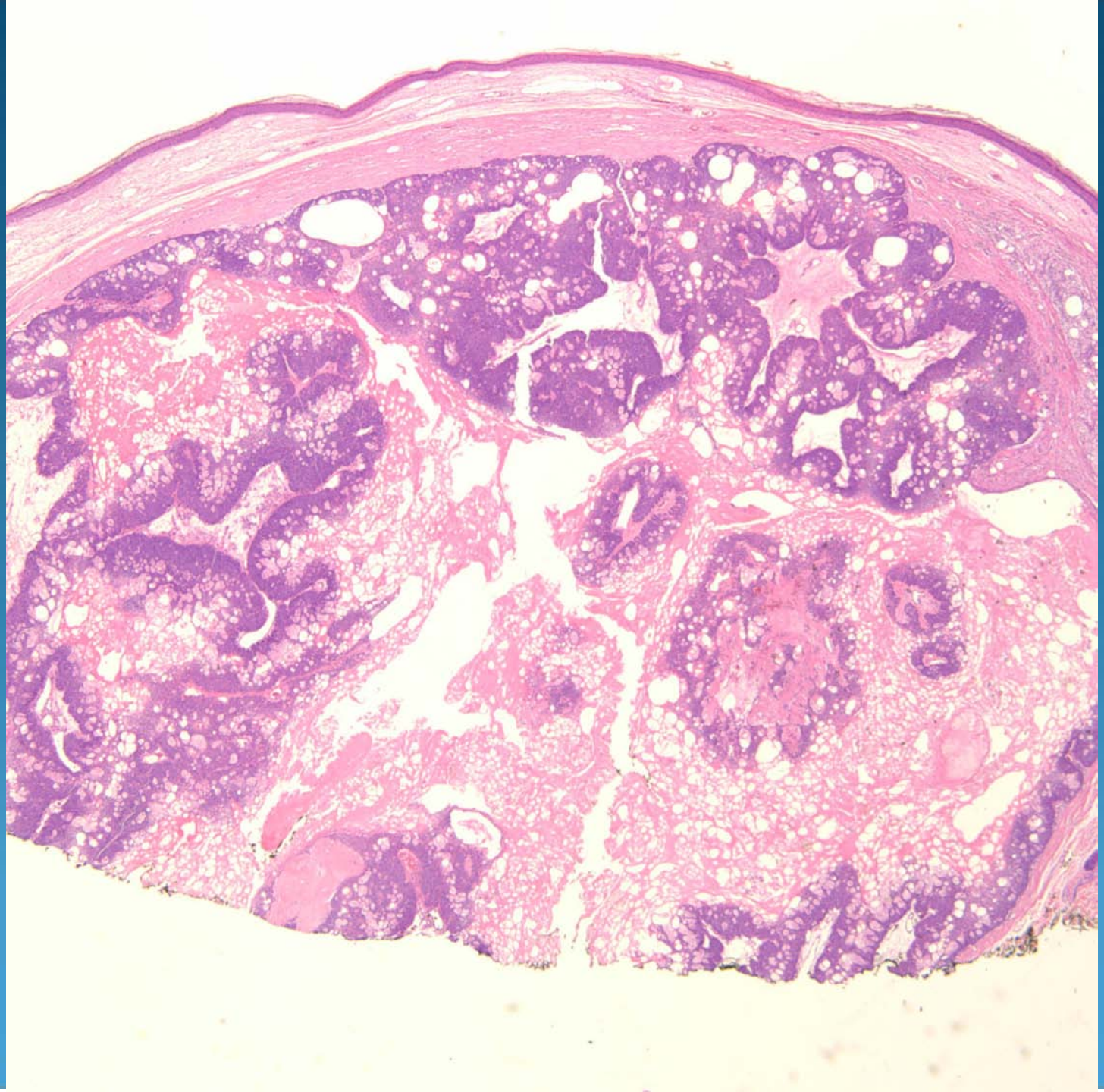

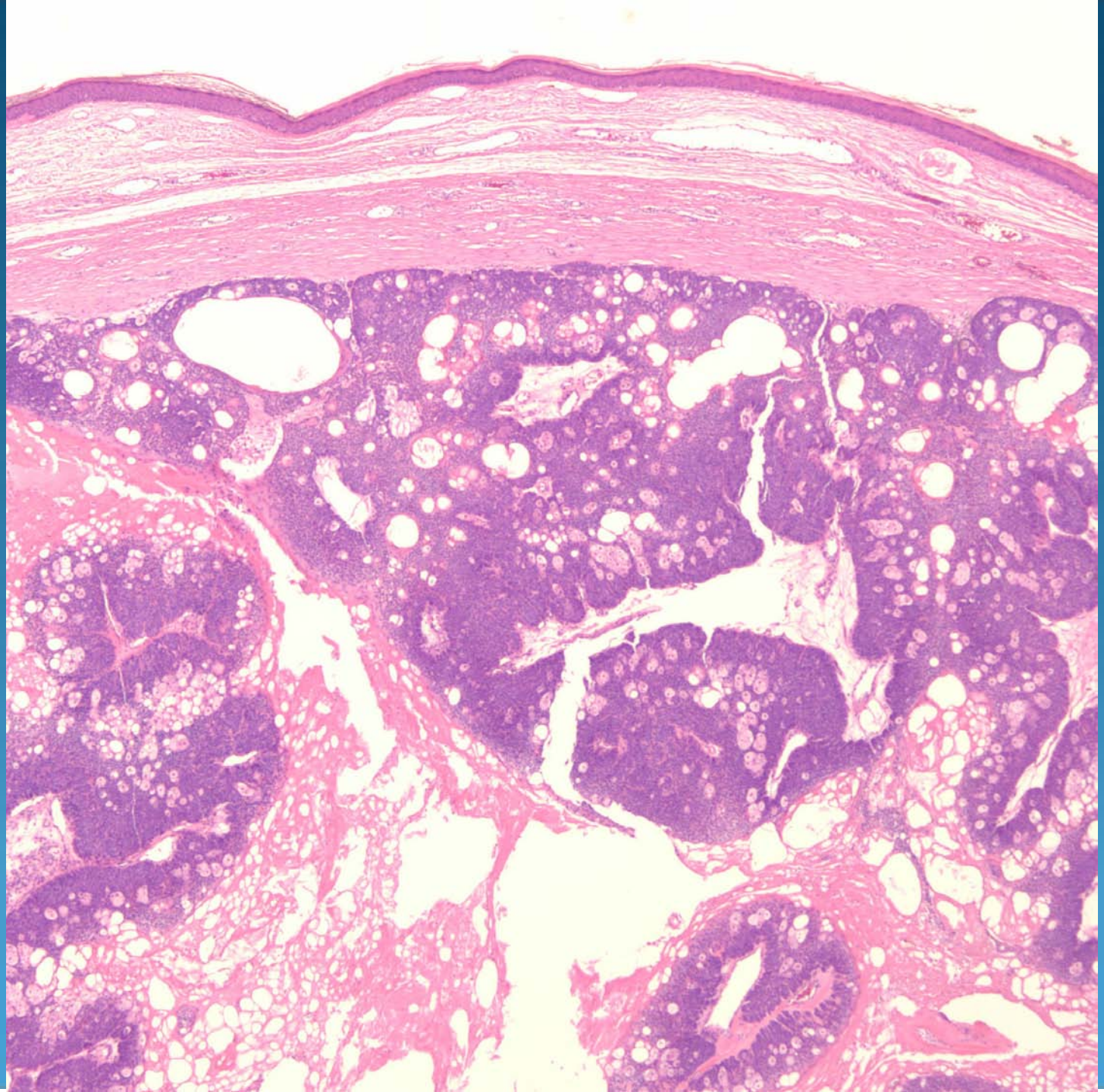

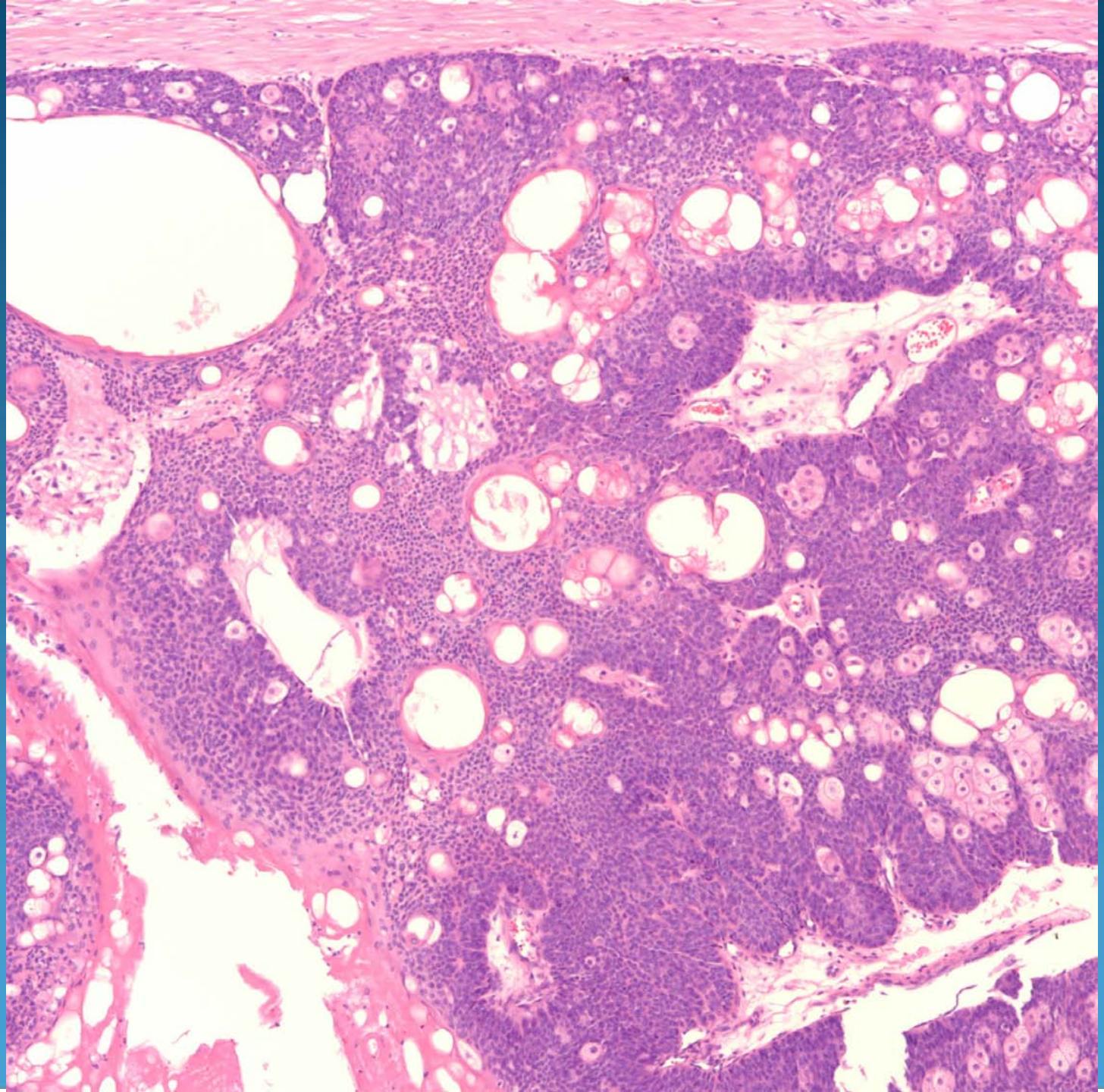

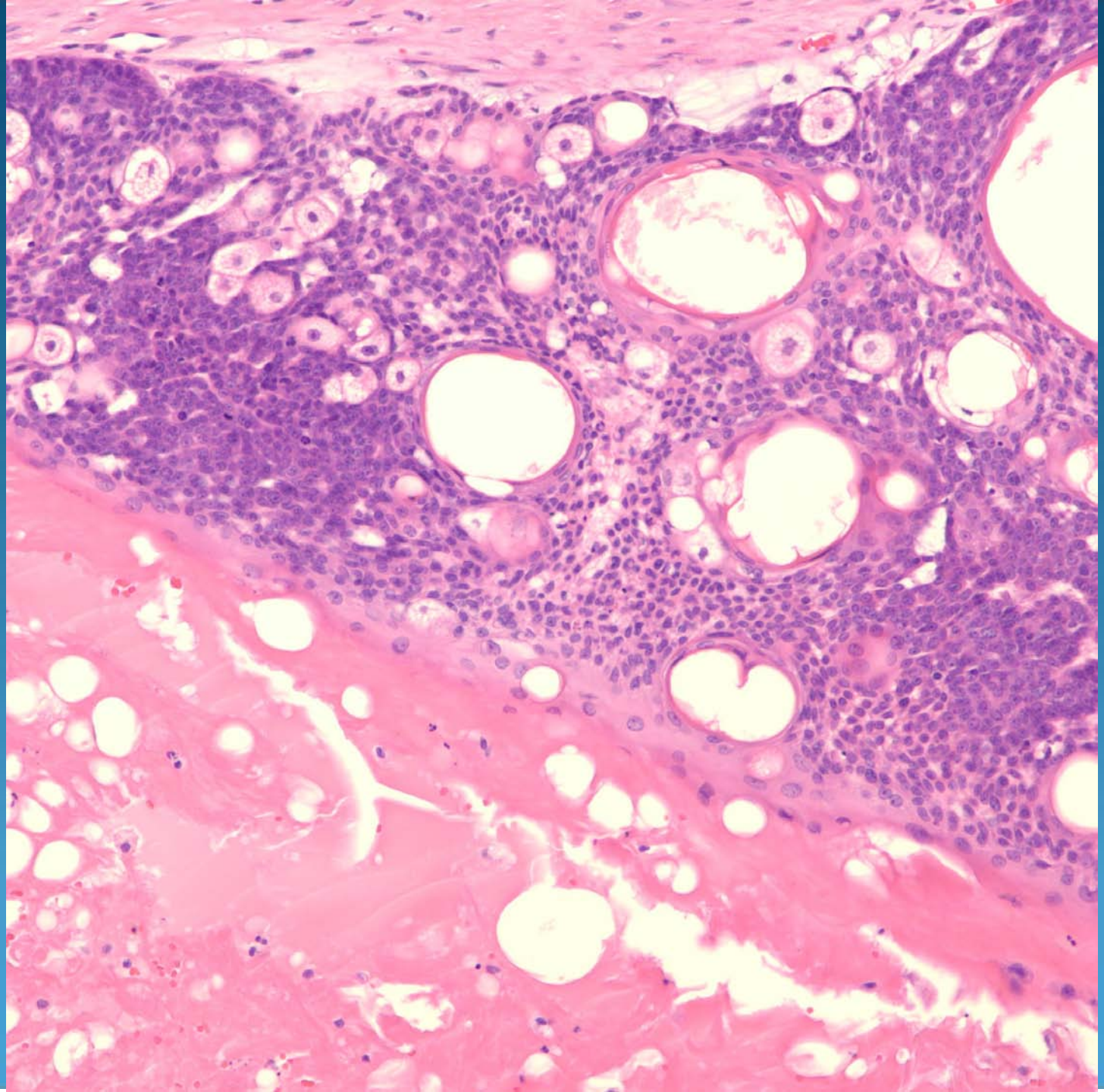

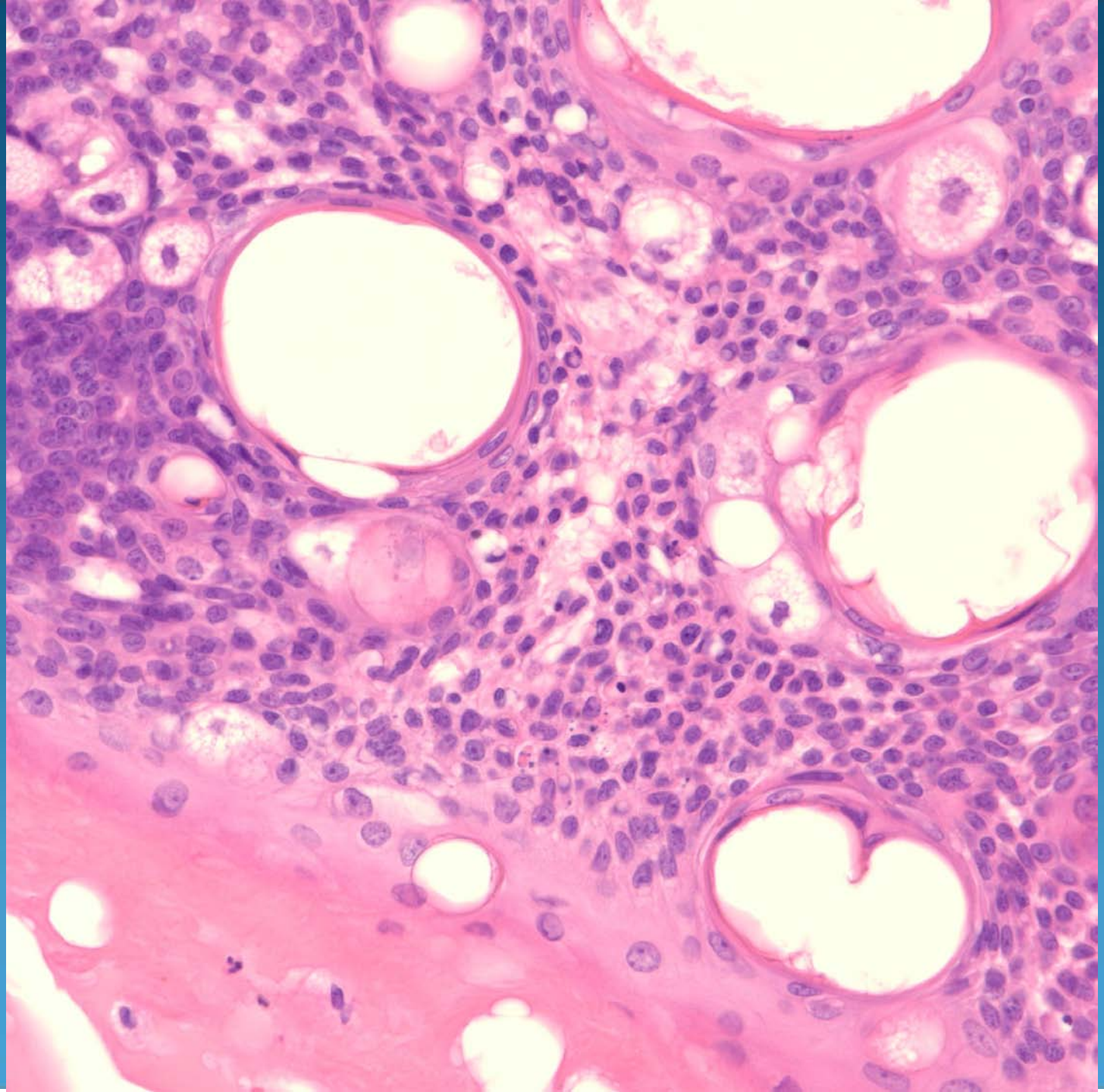

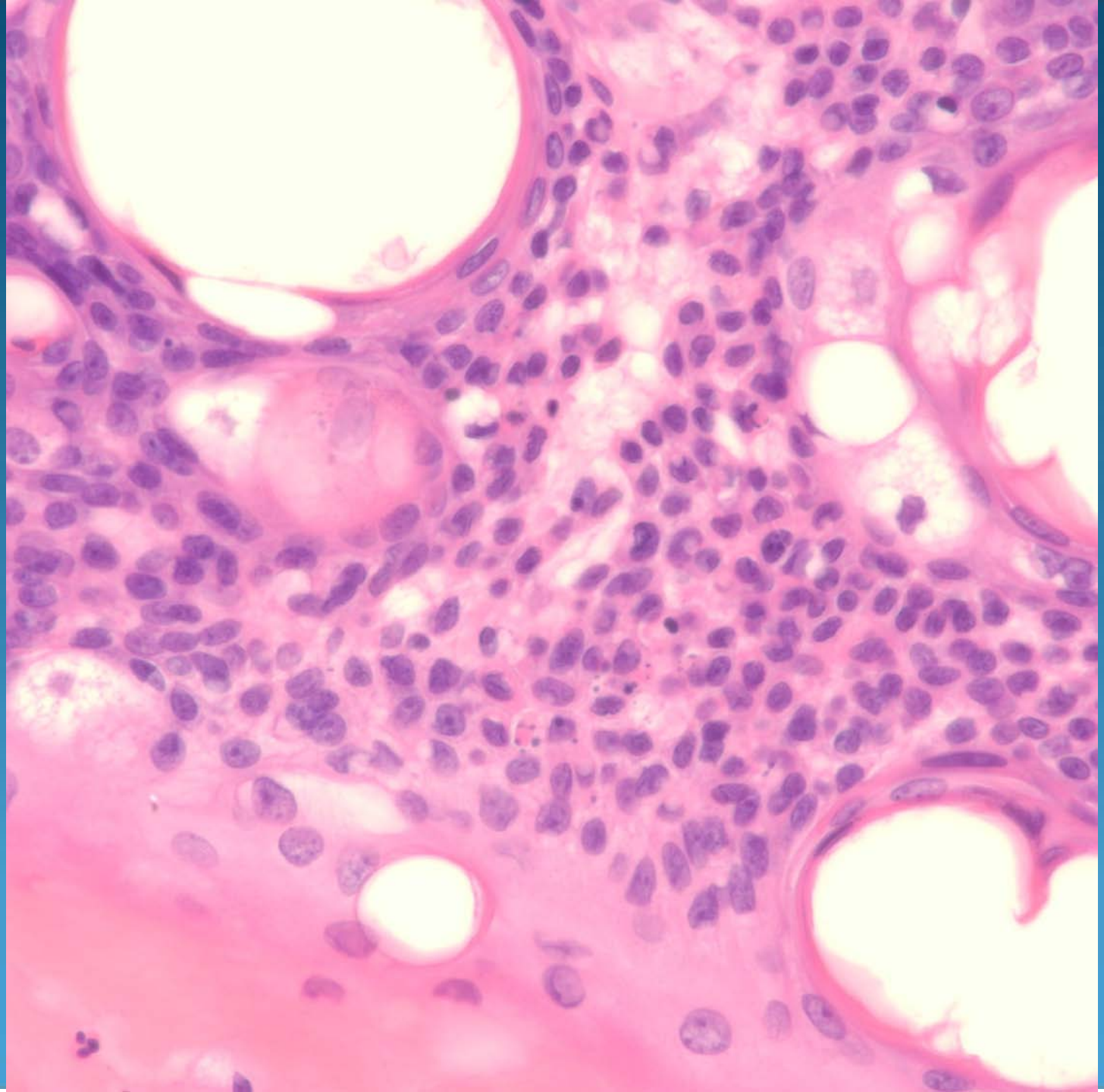

Sebaceoma

Pearls

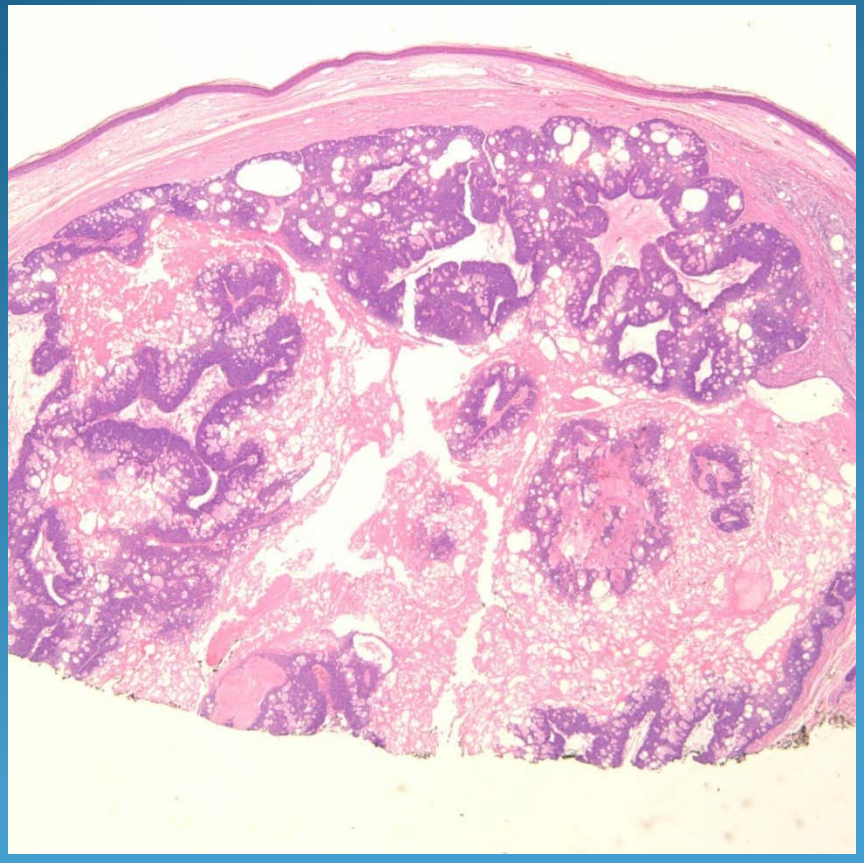

- Circumscribed dermal nodule of basaloid cells with sebocytes in varying stages of maturation
- Large areas of holocrine secretion
- Lacking peripheral palisading

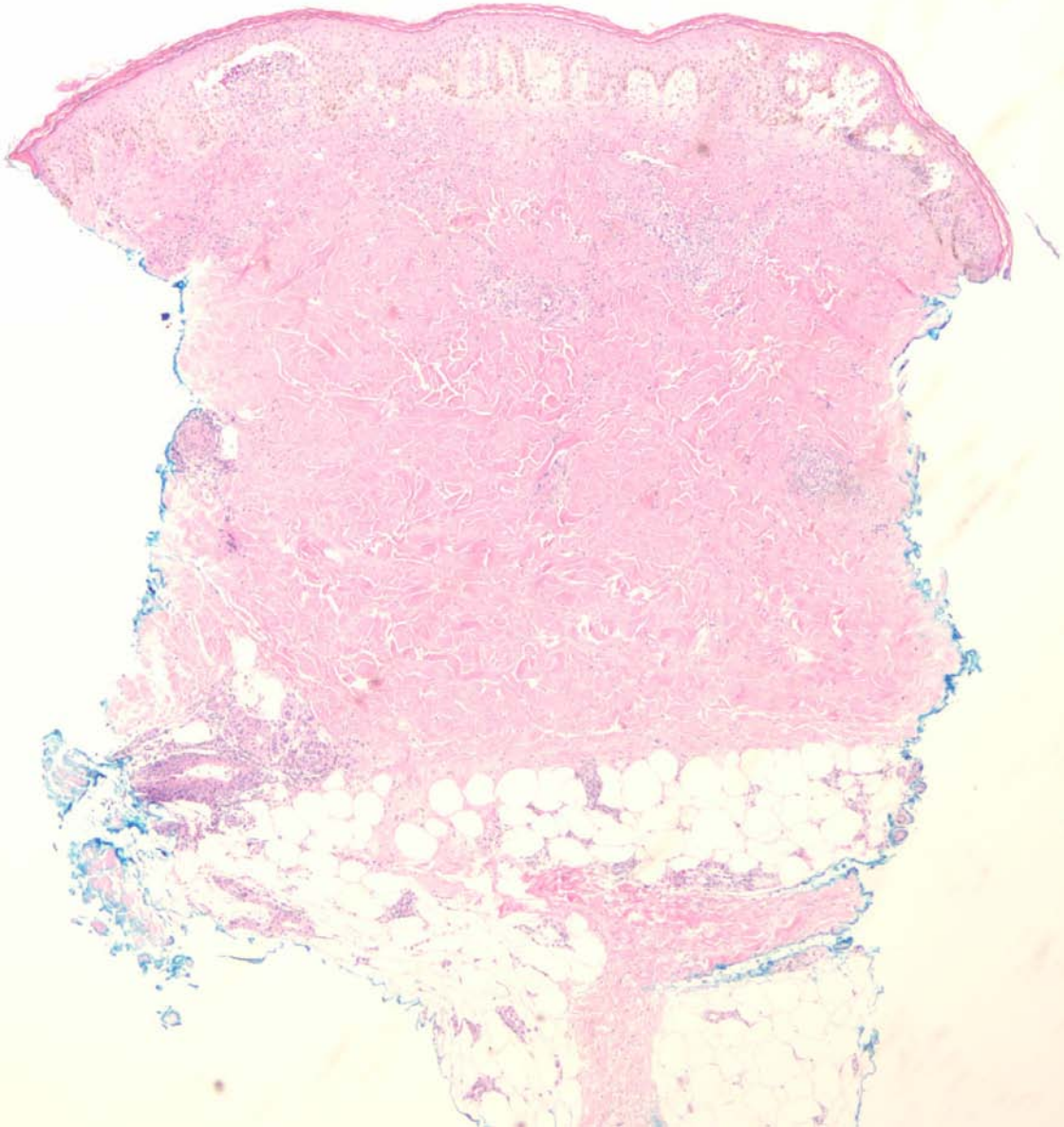

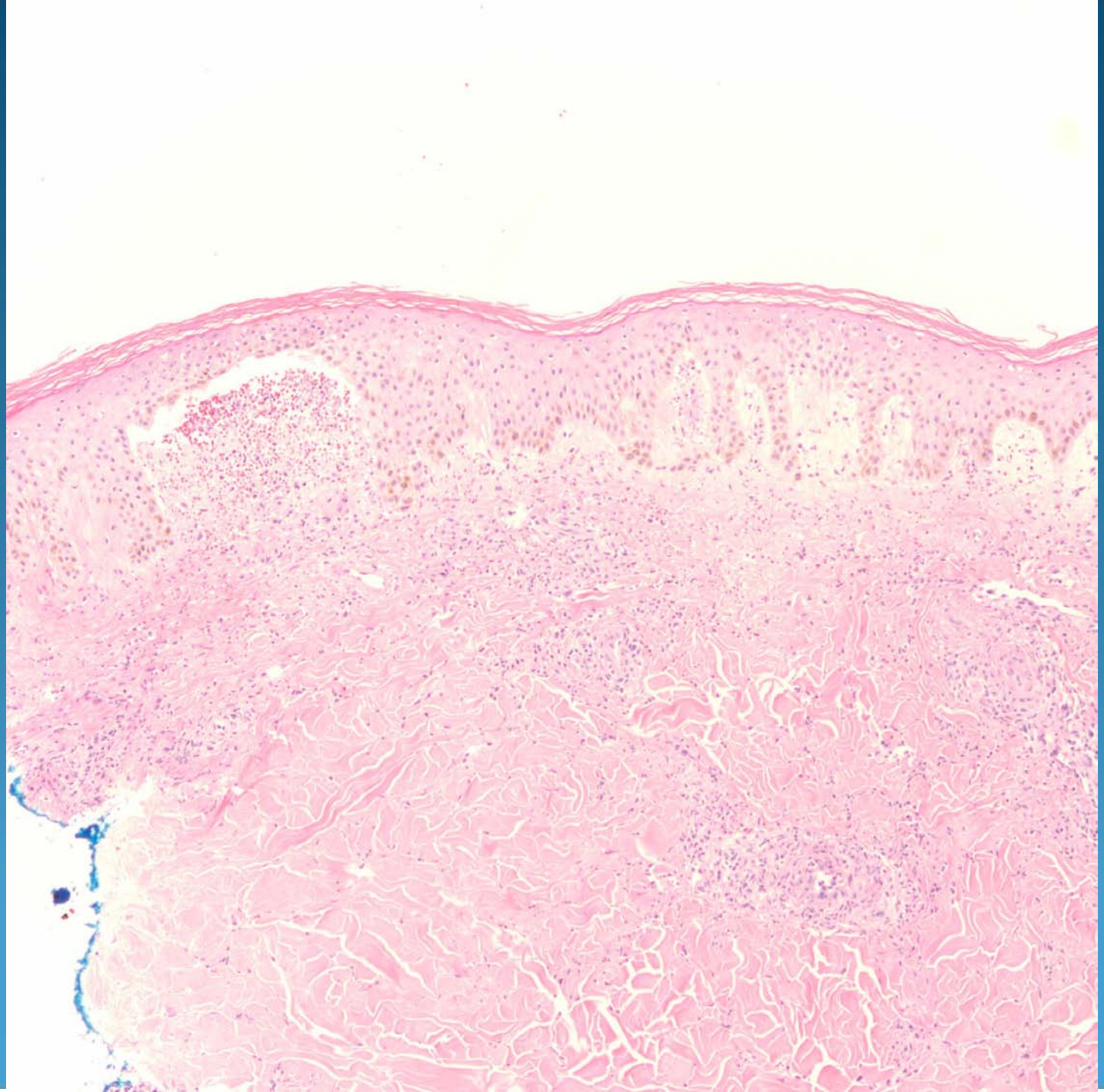

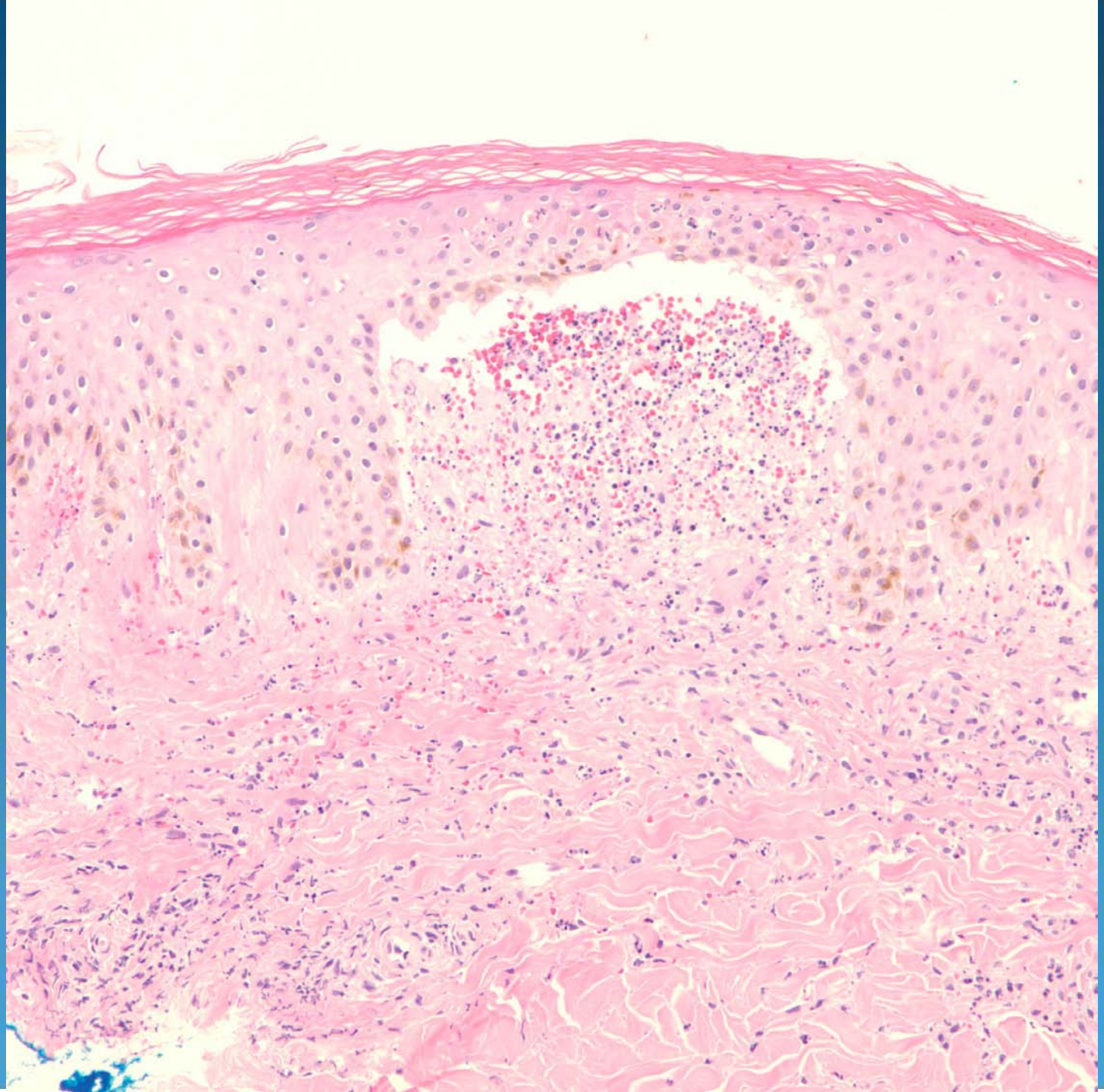

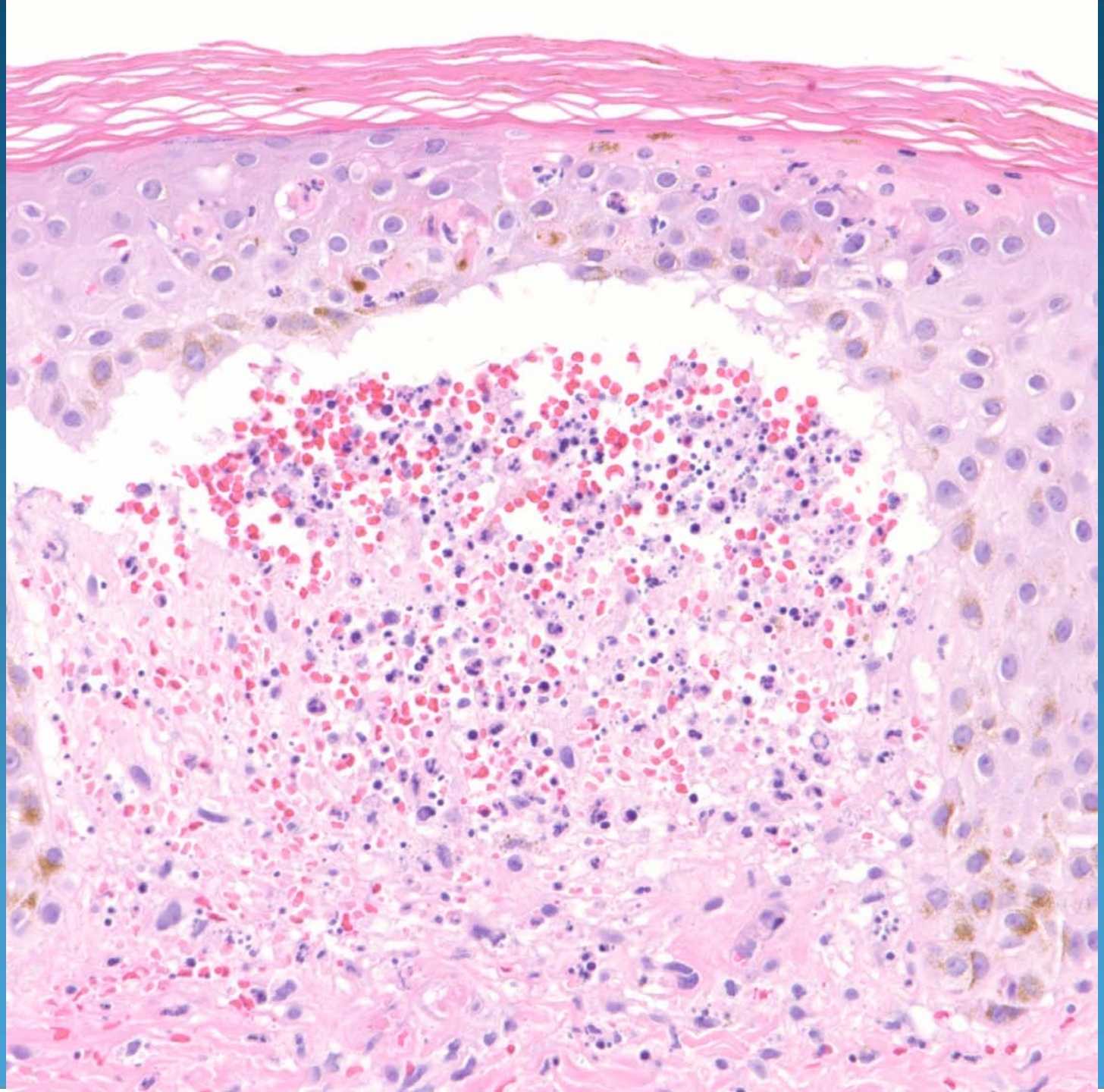

Dermatitis Herpetiformis

Pearls

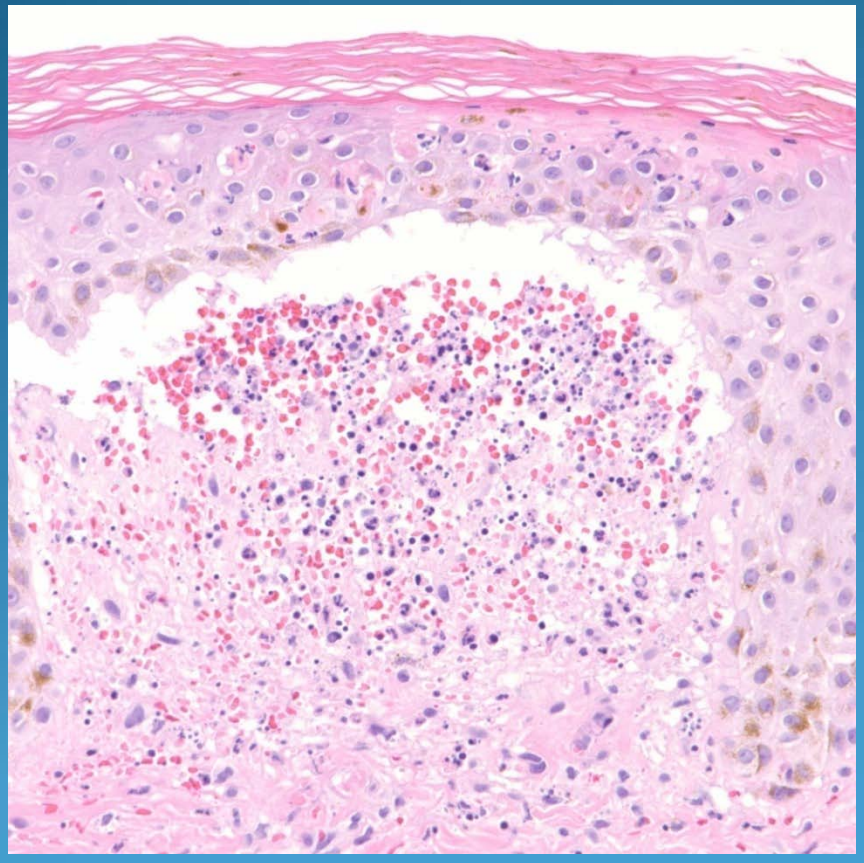

- Papillary dermal microabscesses
- Predominately neutrophils
- Histologically identical with linear IgA disease
- Confirm with DIF

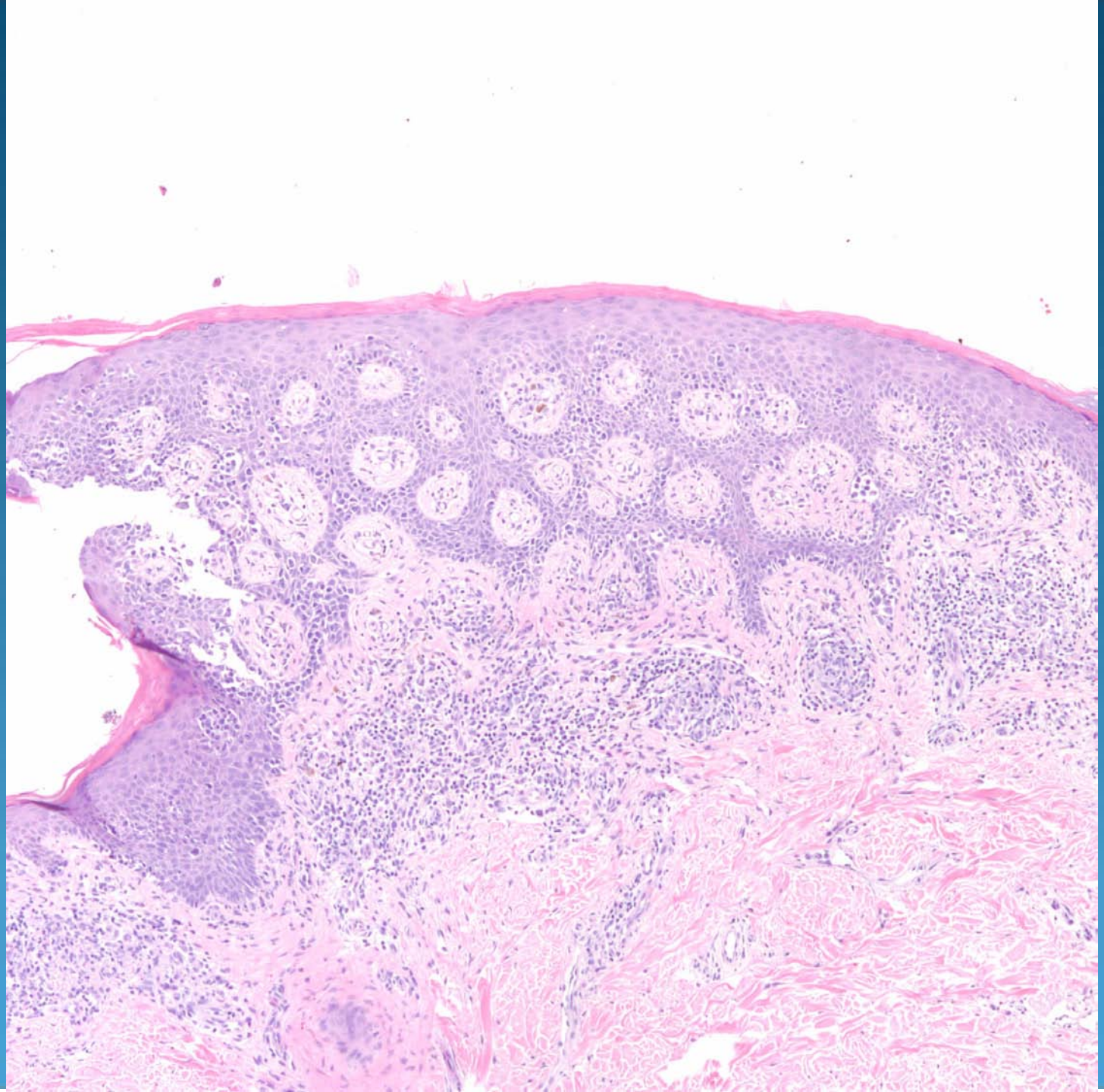

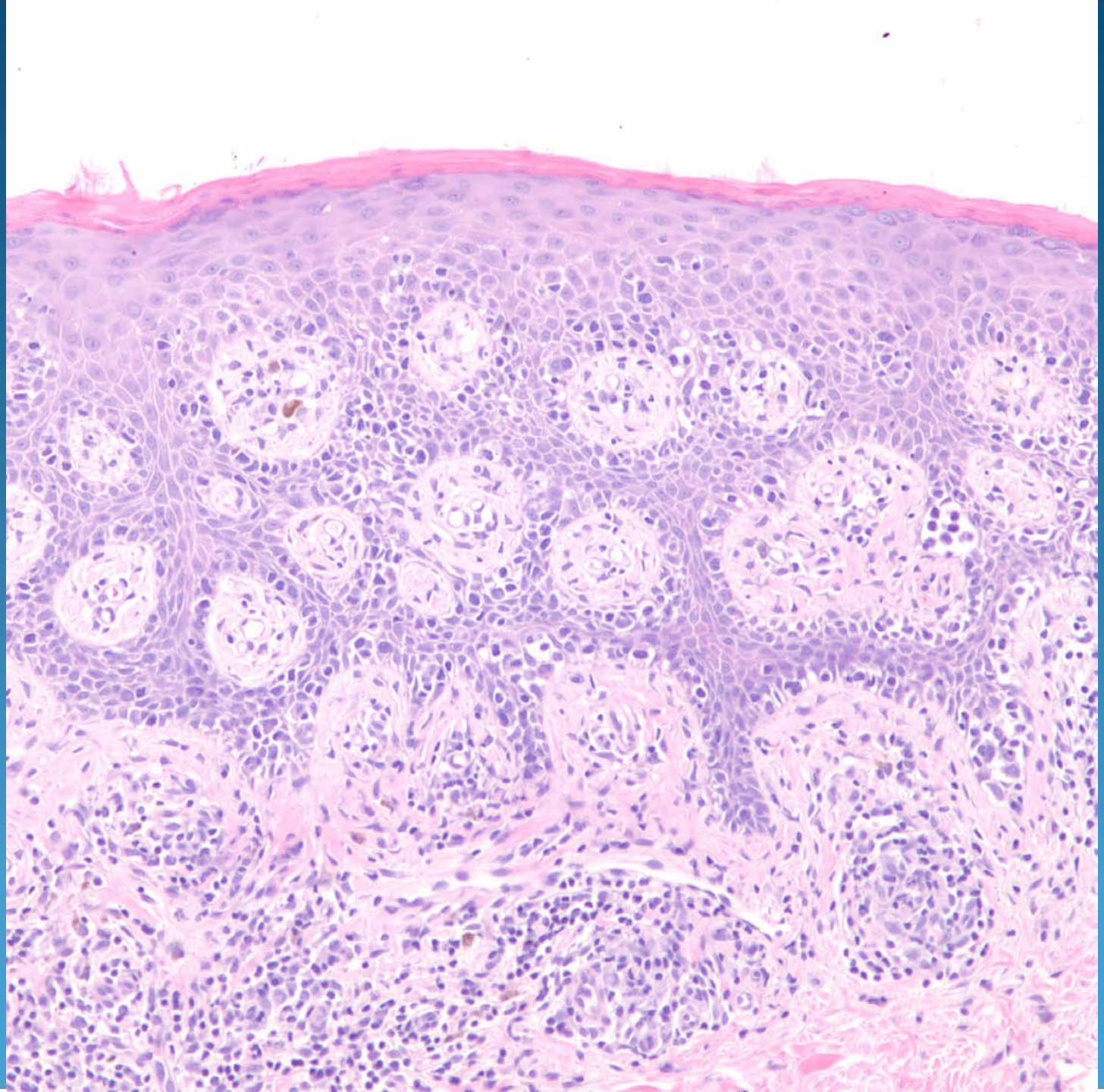

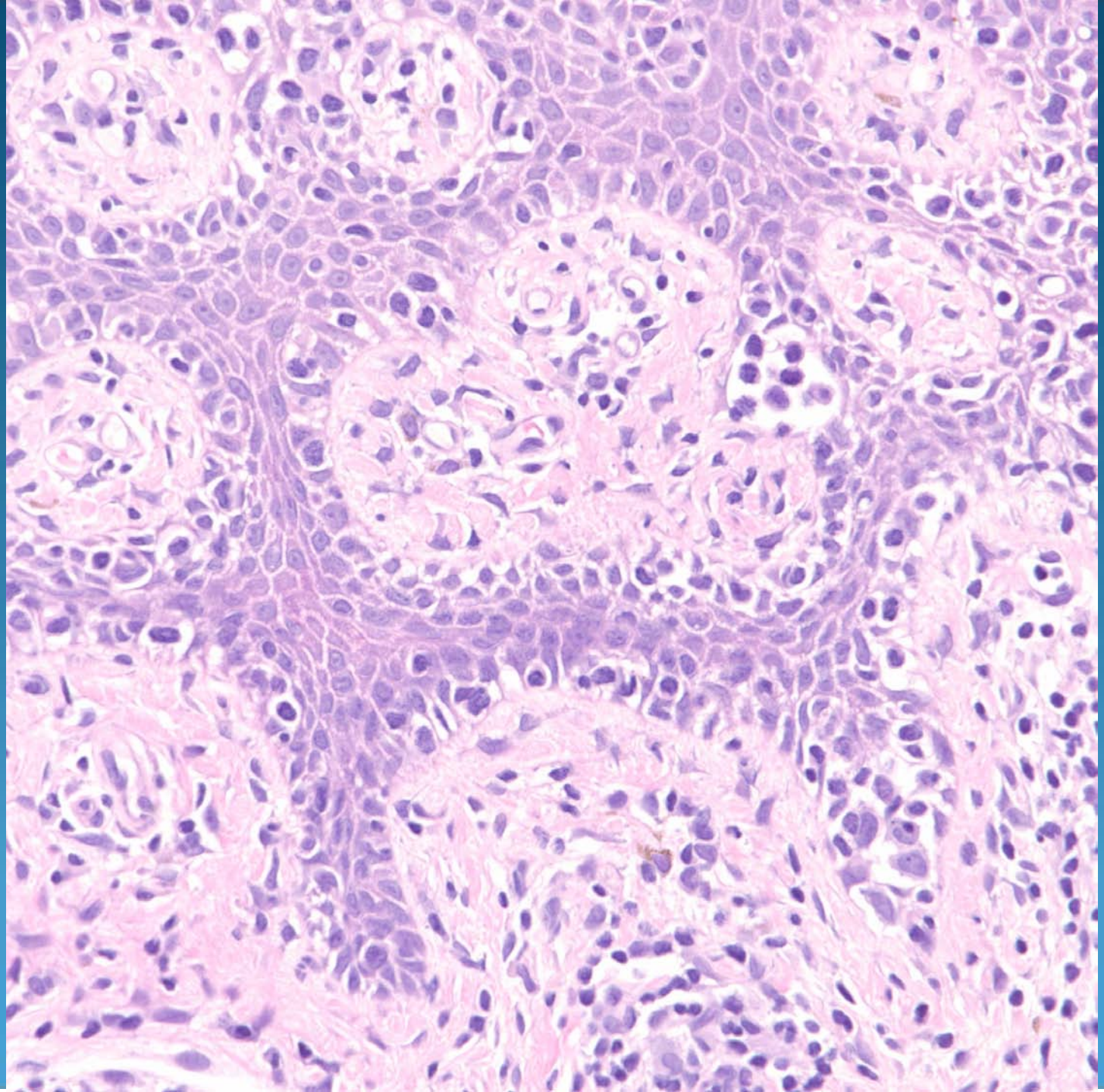

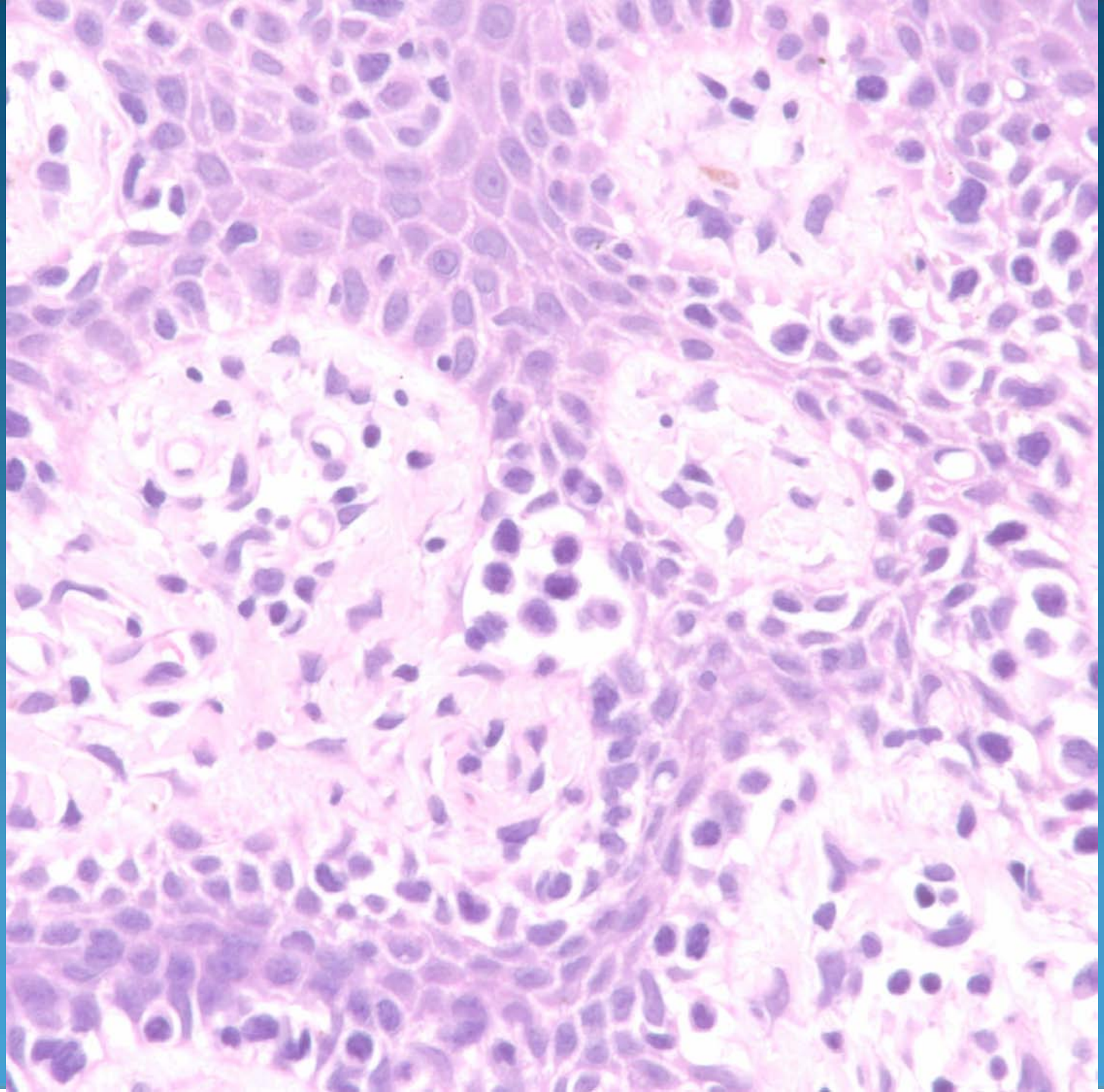

CD4

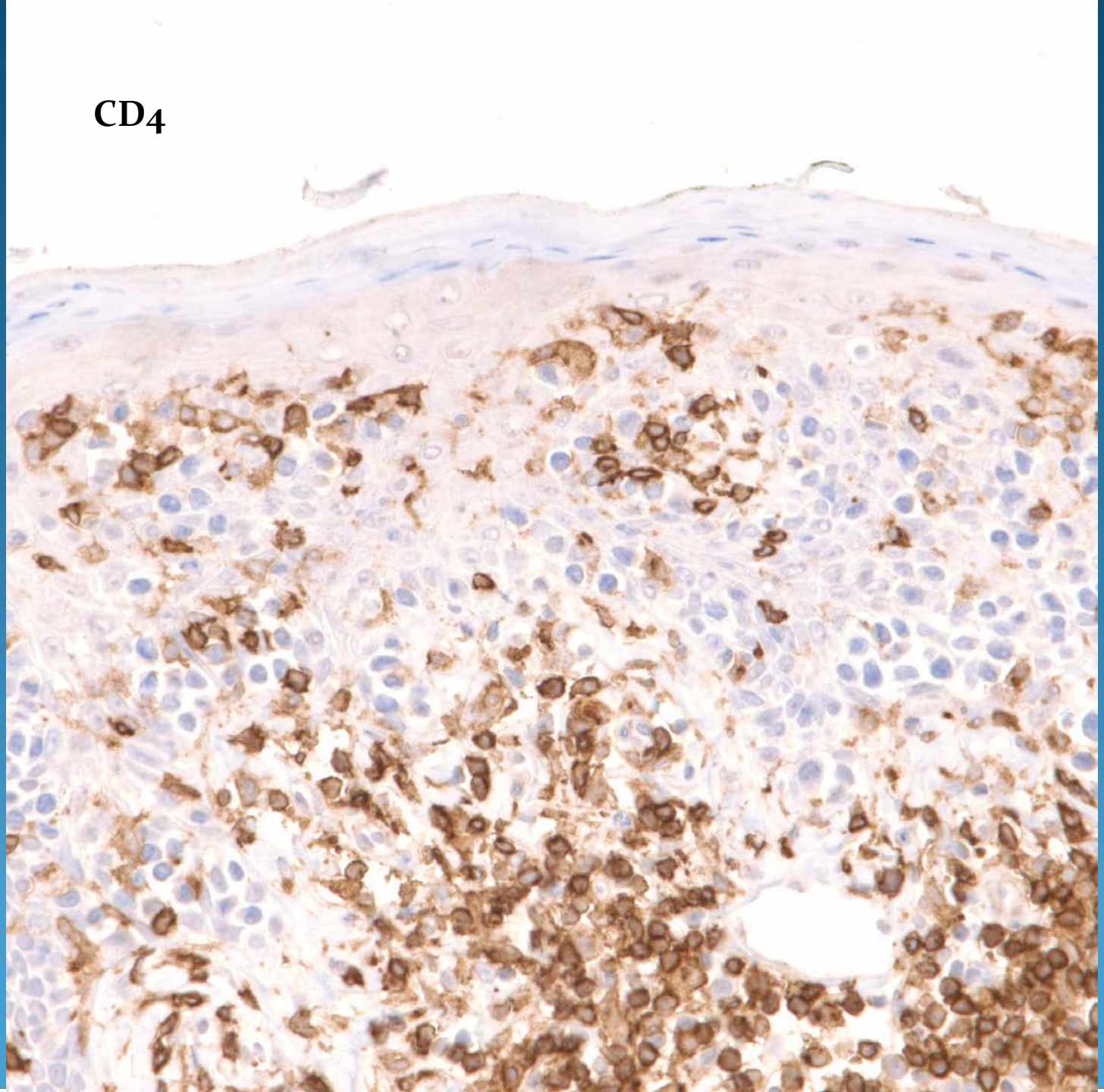

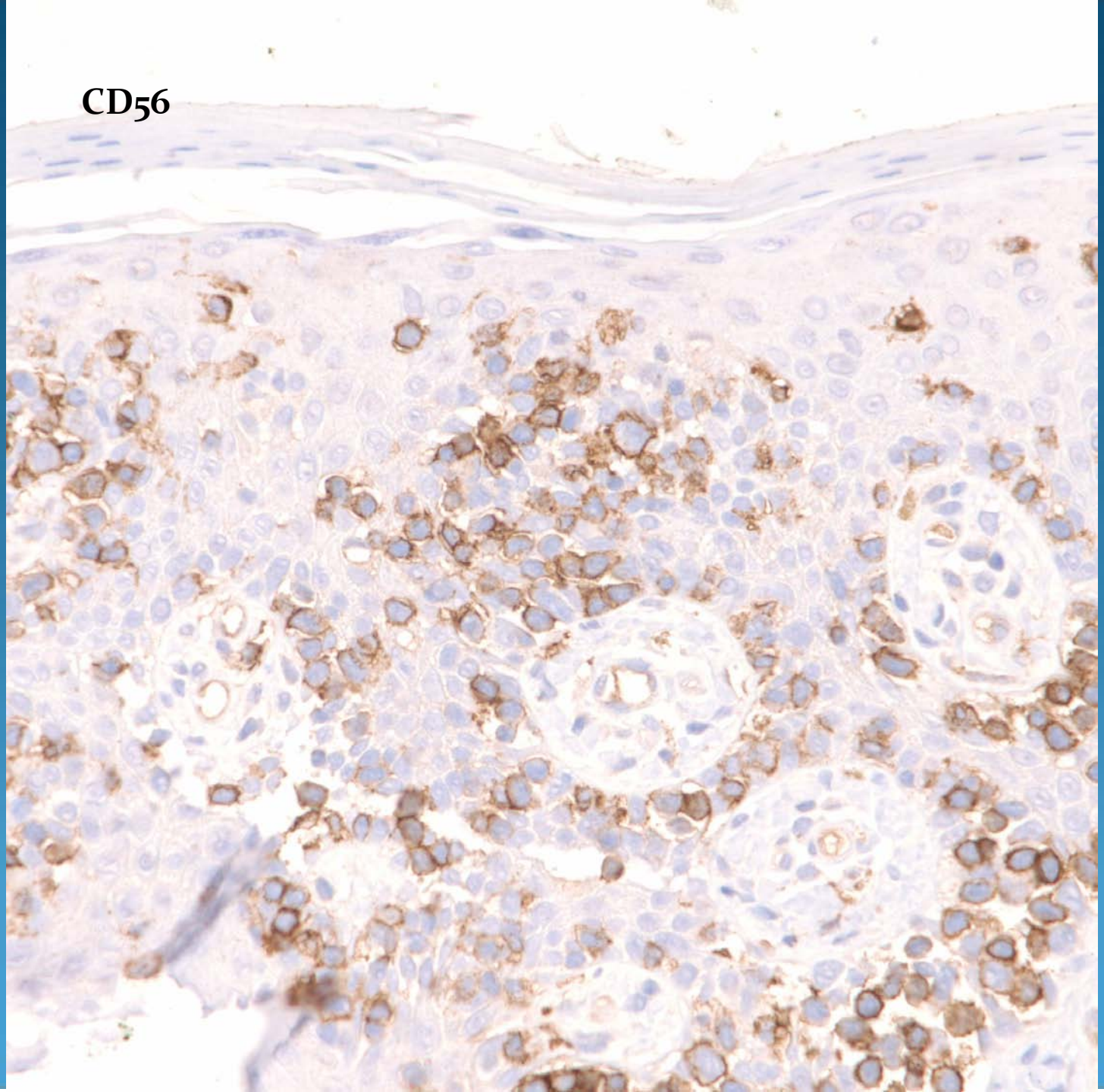
CD56

Mycosis Fungoides with CD56 co-expression

Pearls

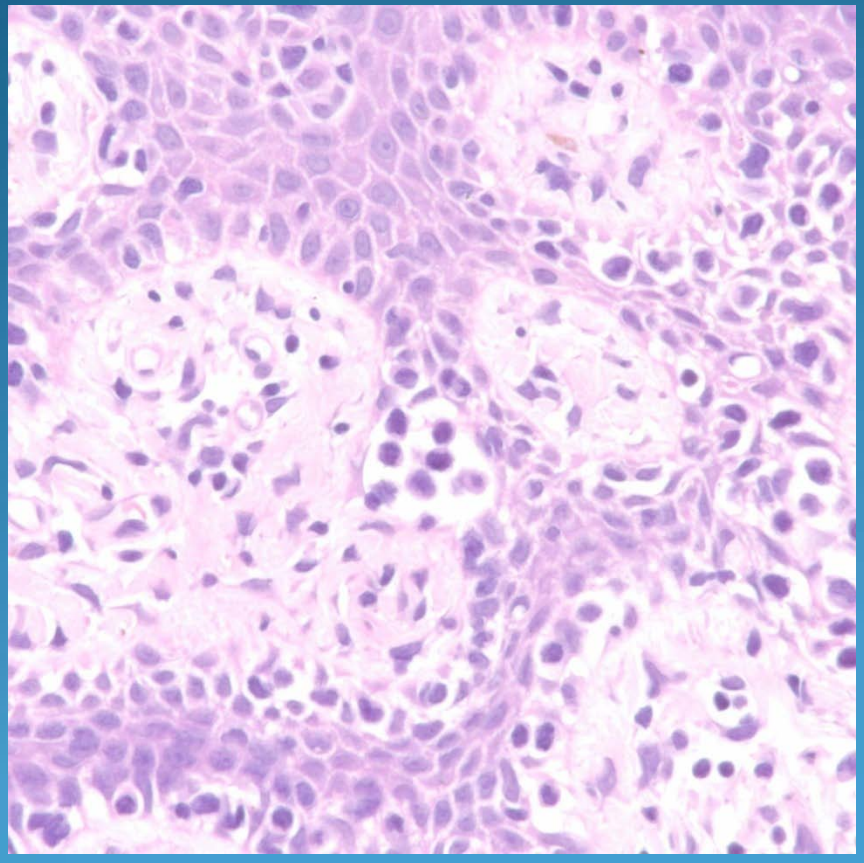

- Basal keratinocytic intercalation with atypical lymphocytes
- Pautrier microabscesses
- Confirm with IHC
  - CD4+
  - CD5 and CD7 –
- CD56+ may portend more aggressive course